








DOI: 10.22363/2313-0245-2024-28-3-36985

EDN: FZDMOW

ОРИГИНАЛЬНОЕ ИССЛЕДОВАНИЕ
ORIGINAL RESEARCH

Proliferation and apoptosis features of ovarian follicles after local irradiation with electrons and platelet-rich plasma administration

Grigory Demyashkin^{1,2}  , Zaira Murtazalieva¹ , Ekaterina Pugacheva¹ ,
Matvey Vadyukhin³ , Makka Bimurzaeva³ ,
Aigul Milovanova³ , Tamara Dengina³ 

¹RUDN University, Moscow, Russian Federation²National Medical Radiological Research Center, Moscow, Russian Federation³Sechenov University, Moscow, Russian Federation dr.dga@mail.ru

Abstract. Relevance. The ovary is strongly radiosensitive organ. Exposure to ionizing radiation can lead to decreased reproductive function, including infertility. One of the promising regenerative substrates is platelet-rich plasma, which contains a large number of biologically active substances. It is necessary to conduct research in this direction in order to determine the dose-dependent effects of electron irradiation on the cell cycle of oocytes and granulosa cells and to assess the risks of developing radiation-induced ovarian failure. It is important to develop methods for the prevention of acute post-radiation complications, which may include platelet-rich plasma injections. **Aim:** immunohistochemical analysis of ovarian structures' cell cycle after administration of platelet-rich plasma in a model of radiation-induced ovarian failure. **Materials and methods.** We divided the animals (Wistar rats; n=40) into four groups: I — control (n=10); II (n=10) — electron irradiation; III (n=10) — administration of platelet-rich plasma before electron irradiation; IV (n=10) — administration of platelet-rich plasma. A morphological assessment and immunohistochemical (Ki-67, caspase 3) examination of the ovaries were performed. **Results and Discussion.** Number of Ki-67-positive granulosa cells were sharply decreased in group II, but in theca cells the level of expression of this marker exceeded control values. Besides, the number of caspase-3-stained cells increased sharply, mainly due to granulosa cells. The immunohistochemical patterns described were less pronounced in the pre-radiation platelet-rich plasma group. **Conclusion.** Components of platelet-rich plasma have radioprotective properties, maintaining the cell cycle of follicular cells and reducing the depth and range of radiation damage to the ovary after 20 Gy electron exposure, confirmed by the Ki-67 and caspase 3 expression levels.

Keywords: ionizing radiation, electrons, ovofolliculogenesis, proliferation, apoptosis

Funding. The authors received no financial support for the research, authorship, and publication of this article.

© Demyashkin G., Murtazalieva Z., Pugacheva E., Vadyukhin M., Bimurzaeva M., Milovanova A., Dengina T., 2024



This work is licensed under a Creative Commons Attribution 4.0 International License
<https://creativecommons.org/licenses/by-nc/4.0/legalcode>

Author contributions. Demyashkin G.A., Murtazalieva Z.M. — concept and design of the study; Pugacheva E.N., Milovanova A.B. — collection and processing of materials; Vadyukhin M.A., Bimurzaeva M.B., Dengina T.A. — analysis of the obtained data, writing the text. All authors made a significant contribution to the development of the concept and manuscript writing, read and approved the final version before publication.

Conflict of interest statement. The authors declare no conflict of interest.

Ethics approval. All manipulations were performed in accordance with the “International Guidelines for Biomedical Research Using Animals” (EEC, Strasbourg, 1985) and the Declaration of Helsinki of the World Medical Association. The study was approved by the Local Ethics Committee of the National Medical Radiological Research Center (protocol No. 25 of 11/10/23).

Acknowledgements — not applicable.

Consent for publication — not applicable.

Received 07.12.2023 Accepted 15.01.2024.

For citation: Demyashkin G, Murtazalieva Z, Pugacheva E, Vadyukhin M, Bimurzaeva M, Milovanova A, Dengina T. Proliferation and apoptosis features of ovarian follicles after local irradiation with electrons and platelet-rich plasma administration. *RUDN Journal of Medicine*. 2024;28(3):311–318. doi: 10.22363/2313-0245-2024-28-3-36985. EDN: FZDMOW.

Introduction

One of the most unfavorable consequences of radiotherapy for malignant neoplasms of the pelvic organs is irradiation of the ovaries, which can lead to the radiation-induced ovarian failure and, as a consequence, infertility [1].

The ovary is very radiosensitive organ [2]. At the molecular level, electron exposure leads to the direct (single and double DNA breaks/crosslinks, chromosomal mutations) and indirect (generation of reactive oxygen (ROS) and nitrogen (RNS) species and lipid peroxidation products) pathomechanisms activation. The life cycle of oocytes is regulated by proliferation (Ki-67), apoptosis (caspase 3) and pro-apoptosis (p53) factors [3, 4]. There is no effective substrate that can prevent radiation-induced apoptosis in ovarian structures for today, and therefore research into new potential radioprotectors remains relevant.

One of the popular regenerative substrates is platelet-rich plasma (PRP) with a large number of biologically active substances containing in the platelets' α -granules: insulin-like growth factor-1 (IGF-1), platelet-derived growth factor (PDGF), transforming growth factor- β (TGF- β 1), vascular endothelial growth factor (VEGF), fibroblasts growth

factor (FGF), interleukin-8, fibronectin, etc. [5]. These molecules promote tissue repair and remodeling by initiating cell proliferation, angiogenesis, chemotaxis, re-epithelization, extracellular matrix synthesis, etc.

A team of authors at the annual conference of the European Society of Human Reproduction and Embryology presented the results of using PRP as a regenerative substrate in gynecology [6]. Intraovarian administration of PRP in women with perimenopause, premature ovarian failure and poor ovarian response to in vitro fertilization led to morphofunctional restoration of the ovaries with stabilization of anti-müllerian hormone (AMH), follicle stimulating hormone (FSH) levels and the number of antral follicles within three months after treatment.

Based on the listed positive effects, it is possible to take a PRP as a regenerative substrate for research not only for wounds healing [7], but also in the radiation-induced damage treatment in certain organs such as the ovary [8, 9].

It is necessary to conduct research in this direction in order to determine the dose-dependent effects of electron irradiation on the proliferation / apoptosis ratio of oocytes and granulosa cells, and to assess the risks of developing radiation-induced ovarian failure. Such work is also necessary to determine the optimal doses of electron therapy for pelvic organs cancer to level out

radiation damage. Particularly important are the search and development of substances with radioprotective properties.

The aim of this study: immunohistochemical analysis of ovarian structures' cell cycle after administration of platelet-rich plasma in a model of radiation-induced ovarian failure.

Materials and methods

Animals for in vivo study

For this research we divided the experimental animals (Wistar rats; n=40) into four groups:

Group I (n=10) — control;

Group II (n=10) — fractional local irradiation with electrons in a summary dose (SD) of 20 Gy;

Group III (n=10) — intraperitoneal administration of leukocyte-poor platelet-rich plasma (LP-PRP) 1 hour before local electron irradiation in a SD of 20 Gy;

Group IV (n=10) — intraperitoneal administration of LP-PRP.

High doses of ketamine + xylazine (i/p) used for animal removing on the 7th day and the first experimental day was the day of the last fraction. All manipulations were kept according to the standard rules: Declaration of Helsinki of the World Medical Association and “International Guidelines for Biomedical Research Using Animals” and approved by the protocol No. 25 of 11/10/23 of the Local Ethics Committee of the National Medical Radiological Research Center.

Morphological study

The ovaries were cut parallel to the sagittal plane (2 mm) and fixed in 10 % formaline after extraction. Then the processing (tissue histological processing apparatus, Leica Biosystems, Germany) were kept under standard conditions and tissues were embedded in paraffin from which serial sections were made (3 μ m thick). Micropreparations were deparaffinized, dehydrated and then stained for morphological research with hematoxylin and eosin.

Morphological examination was carried out at a magnification of $\times 400$ in 10 randomly selected fields of view of the light microscope in 5 random sections

per sample. Digital scanned preparations were obtained using a video microscopy system (Leica DM3000 microscope, Germany; DFC450 C camera) and image processing software (Leica Application Suite V. 4.9.0) for morphometric analysis.

Immunohistochemical (IHC) study

IHC staining was performed according to the standard manufacturer's protocols with monoclonal antibodies to Ki-67 (ThermoFisher, Clone MM1) and Caspase 3 (ThermoFisher, Clone 74T2) as a primary antibodies [10, 11]. A universal two-component HiDef Detection™ HRP Polymer system (Cell Marque, USA), mouse/rabbit anti-IGG, horseradish peroxidase (HRP) and DAB substrate were used to determine secondary antibodies. Antigen unmasking was carried out in a citrate buffer with pH \approx 6.0 in a water bath with a pT Link microprocessor (Dako, Denmark) at a temperature of 95°C for 40 minutes and then by cooling at a temperature of 20°C for 20 minutes. For cell nuclei counterstaining a Mayer's hematoxylin was used. The number of IHC positively stained cells (in %) was counted at a magnification of $\times 400$ in 10 randomly fields of view.

Statistical analysis

For analytical processing of the research results, the Windows package SPSS 12 (IBM Analytics, USA) statistical program was used. The obtained data are presented as mean \pm standard error. Comparisons between groups were carried out using statistical packages and differences were considered significant at p -value < 0.05 .

Results and discussion

In animals of the control and IV groups, the ovary is covered on the outside with single-layer squamous epithelium (mesothelium), deeper — the tunica albuginea, formed by dense fibrous connective tissue with cords extending from it. The ovarian parenchyma is represented by numerous follicles in different stages of development (Fig. 1).

Fractional local electron irradiation led to the radiation-induced ovarian failure within a week. The number of primordial follicles was sharply reduced, and the number

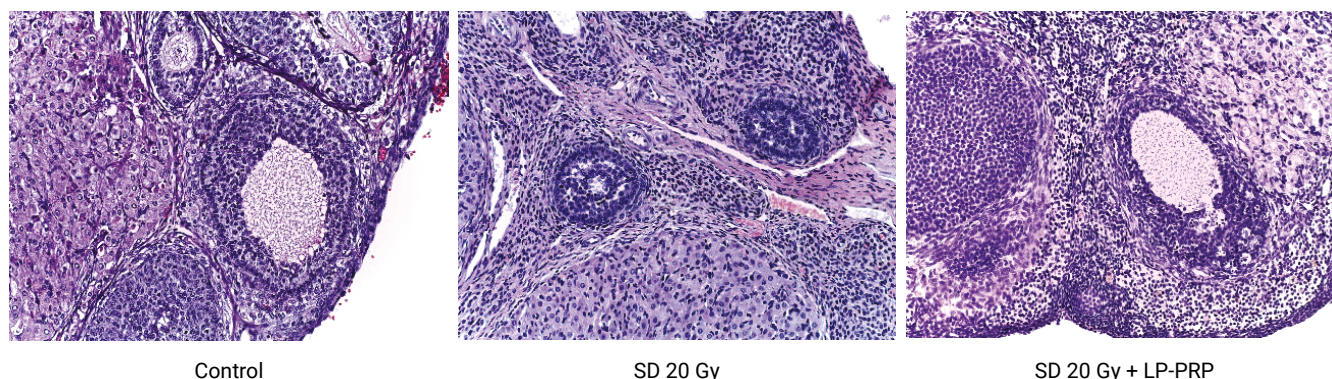


Fig. 1. Ovaries in experimental groups; hematoxylin and eosin stain, magn. $\times 200$

Note: SD – summary dose, LP-PRP – leukocyte poor platelet-rich plasma.

of atretic follicles was increased. In some follicles, oocytes with signs of pyknosis, fragmentation of granulosa cells, and cellular detritus in the antrum were noted. In the stroma of the organ, multiple hemorrhages, stasis of most blood vessels, and proliferation of connective tissue were found compared to the control (Fig. 1).

Administration of platelet-rich plasma before irradiation led to a decrease in the degree of radiation-induced ovarian damage compared to the morphological pattern of group II: the primordial and primary follicles counts was slightly reduced unevenly distributed over the area of the ovary; isolated hemorrhages and stasis of red blood cells in vessels' lumen (Fig. 1).

An immunohistochemical study of ovaries irradiated with a summary dose of 20 Gy revealed a decrease in Ki-67 expression level in the follicles (3.9 times) and the corpus

luteum (1.5 times), while the proportion of Ki-67-positive theca cells sharply increased (7.5 times) compared to the control group. Number of caspase-3-immunopositive granulosa cells increased 3.8 times, while practically no differences in the corpus luteum and theca cells were observed compared to the control (Fig. 2–4).

Administration of LP-PRP in group III led to a partial restoration of the proliferative activity of granulosa cells (2.4 times) compared to the irradiation group, however, the proportion of Ki-67-positive theca cells decreased (1.3 times) compared to Group II. A significant decrease (1.6 times) in the expression of caspase-3 in group III was observed only in granulosa cells compared to the results of the irradiation group.

Although, no statistically significant differences were found between the levels of immunoreactivity in group IV compared to the control.

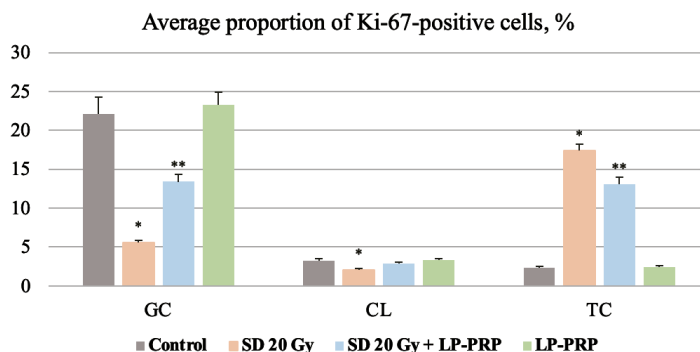


Fig. 2. Count of Ki-67-positive cells in experimental ovaries

Note: GC – granulosa cells, CL – corpus luteum, TC – theca cells, SD – summary dose. For comparison the Kruskal – Wallis test and the Mann – Whitney U test were performed; * – significant differences SD 20 Gy vs control ($p < 0.05$). ** – significant differences SD 20 Gy vs SD 20 Gy + LP-PRP ($p < 0.05$).

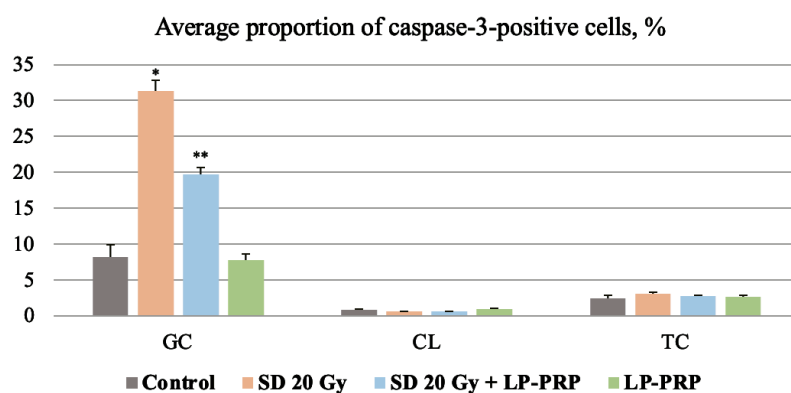


Fig. 3. Count of caspase-3-positive cells in experimental ovaries

Note: GC – granulosa cells, CL – corpus luteum, TC – theca cells, SD – summary dose. For comparison the Kruskal – Wallis test and the Mann – Whitney *U* test were performed. * – significant differences SD 20 Gy vs control ($p < 0.05$). ** – significant differences SD 20 Gy vs SD 20 Gy + LP-PRP ($p < 0.05$).

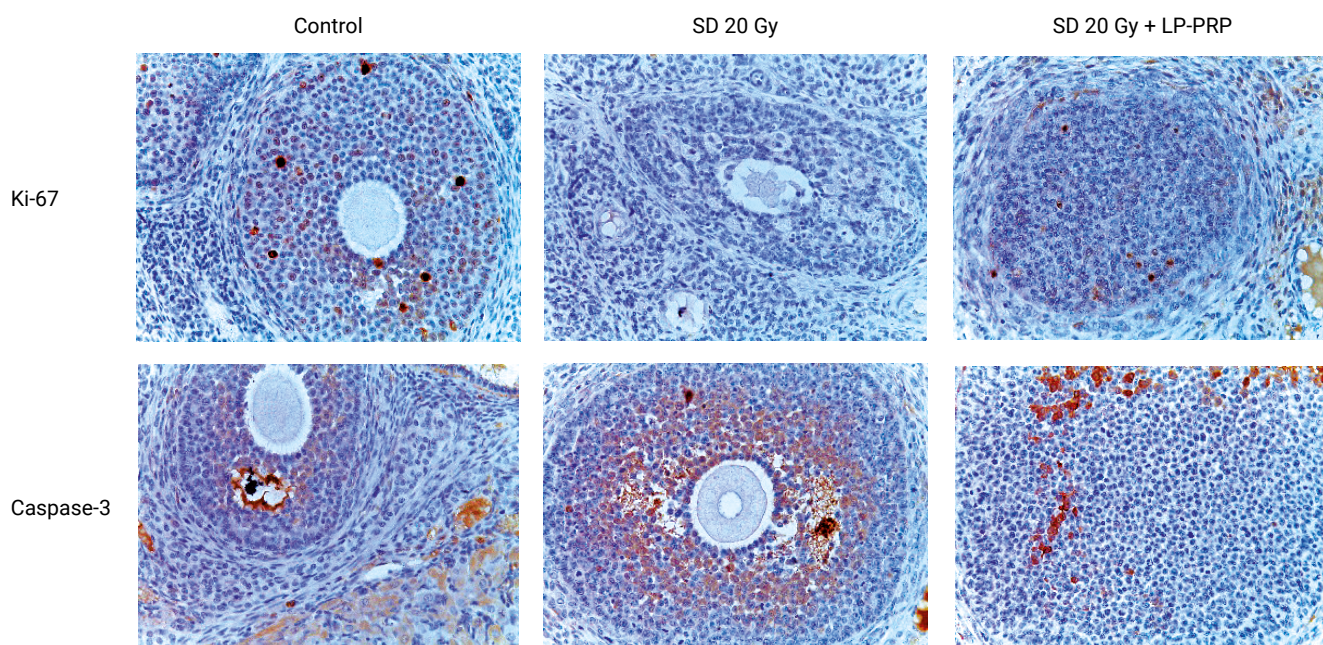


Fig. 4. Immunohistochemical analysis of Ki-67 and caspase-3 expression in experimental ovaries, magn. $\times 400$

Local electron irradiation in group II led to a marked decrease in the Ki-67 expression in granulosa and corpus luteum cells in combination with a sharp increase of caspase-3-stained follicular cells. This is probably because of the effect of electrons on proliferatively active cells which lead to both direct (single and double DNA damages and chromosomal mutations) and indirect (ROS and RNS generation,

lipid peroxidation and molecular water radiolysis) activation of pathways including in post-radiation toxicity in ovaries [12]. Then it leads to a strongly decrease in the primordial follicles number, fibrous connective tissue overgrowth which results in radiation-induced premature ovarian failure with ovarian reserve decrease, early menopause and infertility [13].

Post-radiation cell death most often occurs by apoptosis with activation of the cytochrome *c* and caspase cascade pathways, and in our study, granulosa cells turned out to be the most sensitive to the effects of electron irradiation, which was accompanied by a sharp induction of their apoptosis, confirmed by a high level of caspase-3 expression. Almost similar results were obtained by other researchers [14]. In our opinion a secretory disruption in granulosa cells results to the decreased synthesis of steroid hormones and growth factors. These changes led to the secondary violation of ovofolliculogenesis. In addition, theca cells hyperplasia is also responsible for the secretory follicular dysfunction, and it is the compensatory response to decreased hormone levels in blood.

Due to the fact that electrons lead to a decrease in the synthesis of key growth factors responsible for the restoration and regeneration in ovary, it was advisable to use platelet-rich plasma where the platelets' α -granules contain high concentrations of biologically substances capable of inducing the follicular cells' regenerative activity and metabolism (through neoangiogenesis stimulation) [15, 16]. Thus, the most important of these in PRP are IGF-1, PDGF, TGF- β 1, VEGF, FGF, interleukin-8, fibronectin, etc. [17]

These biologically active molecules are the key factors in proliferation and differentiation of many cell types. Due to this it can restore proliferative-apoptotic balance, probably responsible for the regenerative and radioprotective LP-PRP properties discovered in the present study: higher levels of proliferative activity of granulosa cells combined with significantly lower rates caspase-3 immunoreactivity compared with the irradiation group. In addition, pre-irradiation administration of LP-PRP led to a less pronounced increase in the theca cells proliferation, which may indirectly indicate the body's low need for compensatory-adaptive hyperplasia of these cells and the preservation of close to physiological levels of steroid hormones.

Thus, based on histological and immunohistochemical studies, it was occurred that pre-radiation administration of LP-PRP contributed to the restoration of the proliferation/apoptosis ratio of follicles, which

does not exclude the protective effect of this regenerative substrate, which is especially important for the prevention of the development of radiation-induced ovarian failure.

Conclusion

Components of platelet-rich plasma have radioprotective properties, maintaining the cell cycle of follicular cells and reducing the depth and range of radiation damage to the ovary after 20 Gy electron exposure, confirmed by the Ki-67 and caspase 3 expression levels.

References/Библиографический список

1. Ahmed Y, Khan AMH, Rao UJ, Shaukat F, Jamil A, Hasan SM et al. Fertility preservation is an imperative goal in the clinical practice of radiation oncology: a narrative review. *Ecancermedicalscience*. 2022;16:1461. doi: 10.3332/ecancer.2022.1461
2. Terenziani M, Piva L, Meazza C. Oophoropexy: a relevant role in preservation of ovarian function after pelvic irradiation. *Fertility and Sterility*. 2009;91(3):935.e15–935.e16. doi: 10.1016/j.fertnstert.2008.09.029
3. Kaur S, Kurokawa M. Regulation of Oocyte Apoptosis: A View from Gene Knockout Mice. *International Journal of Molecular Sciences*. 2023;24(2):1345. doi: 10.3390/ijms24021345
4. Zhang W, Huang L, Kong C, Liu J, Luo L, Huang H. Apoptosis of rat ovarian granulosa cells by 2,5-hexanedione in vitro and its relevant gene expression. *Journal of Applied Toxicology*. 2013;33(7):661–669. doi: 10.1002/jat.2714
5. Dawood AS, Salem HA. Current clinical applications of platelet-rich plasma in various gynecological disorders: An appraisal of theory and practice. *Clinical and Experimental Reproductive Medicine*. 2018;45(2):67–74. doi: 10.5653/cerm.2018.45.2.67
6. Sfakianoudis K, Simopoulou M, Grigoriadis S, Pantou A, Tsioulou P, Maziotis E et al. Reactivating Ovarian Function through Autologous Platelet-Rich Plasma Intraovarian Infusion: Pilot Data on Premature Ovarian Insufficiency, Perimenopausal, Menopausal, and Poor Responder Women. *Journal of Clinical Medicine*. 2020;9(6):1809. doi: 10.3390/jcm9061809
7. Xu P, Wu Y, Zhou L. Platelet-rich plasma accelerates skin wound healing by promoting re-epithelialization. *Burns Trauma*. 2020;8: tkaa028. doi:10.1093/burnst/tkaa028
8. Demyashkin GA, Vadyukhin MA, Shekin VI. The Influence of Platelet-Derived Growth Factors on the Proliferation of Germinal Epithelium After Local Irradiation with Electrons. *Journal of Reproduction and Infertility*. 2023;24(2):94–100. doi:10.18502/jri.v24i2.12494
9. Ozcan P, Takmaz T, Tok OE, Islek S, Yigit EN, Ficioglu C. The protective effect of platelet-rich plasma administrated on ovarian function in female rats with Cy-induced ovarian damage. *Journal of Assistant Reproduction and Genetics*. 2020;37(4):865–873. doi: 10.1007/s10815-020-01689-7

10. Kudryavtsev GY, Kudryavtseva LV, Mikhaleva LM, Kudryavtseva YY, Solovyeva NA, Osipov VA, et al. Immunohistochemical study of P53 protein expression in different prostate cancer Gleason grading groups. *RUDN Journal of Medicine*. 2020;24(2):145–155. doi: 10.22363/2313-0245-2020-24-2-145-155
11. Kudryavtsev GY, Kudryavtseva LV, Mikhaleva LM, Babichenko II. Immunohistochemical Study of Tumor Cells Proliferative Activity at Different Graduations of Prostate Cancer. *RUDN Journal of Medicine*. 2019;23(4):364–372. doi: 10.22363/2313-0245-2019-23-4-364-372
12. Reisz JA, Bansal N, Qian J, Zhao W, Furdai CM. Effects of ionizing radiation on biological molecules — mechanisms of damage and emerging methods of detection. *Antioxidants Redox Signals*. 2014;21(2):260–292. doi:10.1089/ars.2013.5489
13. An J, Du X, Zhang F, Chen J, Dai J, Huang M et al. Effect of radiotherapy on ovarian function in patients with cervical cancer undergoing radical surgery. *Chinese Journal of Radiation Oncology*. 2019;28(10):753–756.
14. Almeida CP, Ferreira MCF, Silveira CO, Campos JR, Borges IT, Baeta PG et al. Clinical correlation of apoptosis in human granulosa cells—A review. *Cell Biology International*. 2018;42(10):1276–1281. doi: 10.1002/cbin.11036
15. Seckin S, Ramadan H, Mouanness M, Kohansieh M, Merhi Z. Ovarian response to intraovarian platelet-rich plasma (PRP) administration: hypotheses and potential mechanisms of action. *Journal of Assistant Reproduction and Genetics*. 2022;39(1):37–61. doi:10.1007/s10815-021-02385-w
16. Bos-Mikich A, de Oliveira R, Frantz N. Platelet-rich plasma therapy and reproductive medicine. *Journal of Assistant Reproduction and Genetics*. 2018;35(5):753–756. doi: 10.1007/s10815-018-1159-8
17. Sills ES, Wood SH. Autologous activated platelet-rich plasma injection into adult human ovary tissue: molecular mechanism, analysis, and discussion of reproductive response. *Bioscience Rep*. 2019;39(6): BSR20190805. doi: 10.1042/BSR20190805


Особенности пролиферации и апоптоза овариальных фолликулов после локального облучения электронами и введения плазмы, обогащенной тромбоцитами

Г.А. Демьяшкин^{1,2}  , З.М. Муртазалиева¹ , Е.Н. Пугачева¹ , М.А. Вадюхин³ ,
М.Б. Бимурзаева³ , А.Б. Милованова³ , Т.А. Деньгина³ 

¹ Российский университет дружбы народов, г. Москва, Российская Федерация

² Национальный медицинский исследовательский центр радиологии, г. Москва, Российская Федерация

³ Первый Московский государственный университет им. И.М. Сеченова, г. Москва, Российская Федерация

 dr.dga@mail.ru

Аннотация. *Актуальность.* Яичник является одним из наиболее радиочувствительных органов. Воздействие ионизирующего излучения может приводить к снижению репродуктивной функции вплоть до бесплодия. Одним из многообещающих регенеративных субстратов является плазма, обогащенная тромбоцитами (PRP), которая содержит в своем составе большое количество биологически активных веществ. Необходимо проведение исследований в этом направлении с целью определения дозозависимых эффектов облучения электронами на пролиферацию и апоптоз ооцитов и клеток гранулезы, а также оценки рисков развития радиационно-индуцированной овариальной недостаточности. Важное значение имеет разработка методов профилактики острых постлучевых осложнений, в рамках которой возможно применение плазмы, обогащенной тромбоцитами. *Цель:* иммуногистохимическая оценка пролиферации и апоптоза структур яичника после введения плазмы, обогащенной тромбоцитами, в модели радиационно-индуцированной овариальной недостаточности. *Материалы и методы.* Крысы породы Вистар (n=40) были поделены на группы: I — контрольная (n=10); II (n=10) — облучение электронами; III (n=10) — введение плазмы, обогащенной тромбоцитами, до облучения электронами; IV (n=10) — введение плазмы, обогащенной тромбоцитами. Проводили морфологическую оценку и иммуногистохимическое исследование яичников с антителами к Ki-67 и каспазе-3. *Результаты и обсуждение.* В фолликулах яичников II-ой группы отмечали резкое снижение доли Ki-67-позитивных гранулезных клеток, однако в тека-клетках уровень экспрессии этого маркера превышал контрольные значения. В то же время, количество каспаза-3-окрашенных клеток резко возрастало, преимущественно за счет гранулезных клеток. Описанные иммуногистохимические паттерны были менее выражены в группе предлучевого введения плазмы,

обогащенной тромбоцитами. **Выводы.** Компоненты плазмы, обогащенной тромбоцитами, обладают радиопротективным свойством, поддерживая пролиферативно-апоптотический баланс фолликулярных клеток и снижая глубину и диапазон лучевого поражения яичника при воздействии фракционного локального облучения электронами в суммарной дозе 20 Гр, подтвержденной уровнями экспрессии Ki-67 и каспазы-3.

Ключевые слова: ионизирующее излучение, электроны, овофолликулогенез, пролиферация, апоптоз

Информация о финансировании. Авторы заявляют об отсутствии финансирования.

Вклад авторов. Демяшкин Г.А., Муртазалиева З.М. — концепция и дизайн исследования; Пугачева Е.Н., Милованова А.Б. — сбор и обработка материалов; Вадюхин М.А., Бимурзаева М.Б., Деньгина Т.А. — анализ полученных данных, написание текста. Все авторы внесли существенный вклад в разработку концепции, подготовку статьи, прочли и одобрили финальную версию перед публикацией.

Информация о конфликте интересов: авторы заявляют об отсутствии конфликта интересов.

Этическое утверждение. Все манипуляции проводили в соответствии с «Международными рекомендациями по биомедицинским исследованиям на животных» (ЕЕС, Страсбург, 1985 г.) и Хельсинкской декларацией Всемирной медицинской ассоциации. Исследование одобрено Локальным этическим комитетом Национального медицинского исследовательского центра радиологии (протокол № 25 от 10.11.23).

Благодарности — неприменимо.

Информированное согласие на публикацию — неприменимо.

Поступила 07.12.2023. Принята 15.01.2024.

Для цитирования: Demyashkin G., Murtazalieva Z., Pugacheva E., Vadyukhin M., Bimurzaeva M., Milovanova A., Dengina T. Proliferation and apoptosis features of ovarian follicles after local irradiation with electrons and platelet-rich plasma administration // Вестник Российского университета дружбы народов. Серия: Медицина. 2024. Т. 28. № 3. С. 311–318. doi: 10.22363/2313-0245-2024-28-3-36985. EDN: FZDMOW.

Corresponding author: Grigory Alexandrovich Demyashkin — PhD, MD, Leading Researcher at the Scientific and Educational Resource Center “Innovative Technologies of Immunophenotyping, Digital Spatial Profiling and Ultrastructural Analysis” of the RUDN University, Head of the Department of Pathomorphology of the National Medical Research Radiological Center of the Ministry of Health of the Russian Federation, 117198, Miklukho-Maklaya St, 6, Moscow, Russian Federation. E-mail: dr.dga@mail.ru.

Demyashkin G. ORCID 0000-0001-8447-2600

Murtazalieva Z. ORCID 0009-0000-2361-7618

Pugacheva E. ORCID 0009-0009-2268-3838

Vadyukhin M. ORCID 0000-0002-6235-1020

Bimurzaeva M. ORCID 0000-0002-3065-0755

Milovanova A. ORCID 0009-0007-9681-5704

Dengina T. ORCID 0009-0002-0651-9711

Ответственный за переписку: Григорий Александрович Демяшкин — доктор медицинских наук, ведущий научный сотрудник Научно-образовательного ресурсного центра «Инновационные технологии иммунофенотипирования, цифрового пространственного профилирования и ультраструктурного анализа» Российского университета дружбы народов имени Патриса Лумумбы, заведующий отделом патоморфологии Национального медицинского исследовательского центра радиологии Минздрава РФ, Российская Федерация, 117198, г. Москва, ул. Миклухо-Маклая, 6. E-mail: dr.dga@mail.ru

Демяшкин Г. SPIN 5157-0177; ORCID 0000-0001-8447-2600

Муртазалиева З. SPIN 2847-2984; ORCID 0009-0000-2361-7618

Пугачева Е. SPIN 5784-9384; ORCID 0009-0009-2268-3838

Вадюхин М. SPIN 9485-7722; ORCID 0000-0002-6235-1020

Бимурзаева М. SPIN 2637-5894; ORCID 0000-0002-3065-0755

Милованова А. SPIN 9590-8578; ORCID 0009-0007-9681-5704

Деньгина Т. SPIN 5877-3869; ORCID 0009-0002-0651-9711