




DOI: 10.22363/2313-0245-2024-28-1-57-67  
EDN: UCWVAI

REVIEW  
ОБЗОРНАЯ СТАТЬЯ

## Techniques for conservative treatment of peri-implantitis

Lyubov A. Burlakova  , Alexander B. Dymnikov 

RUDN University, Moscow, Russian Federation  
 [shererrrr9@gmail.com](mailto:shererrrr9@gmail.com)

**Abstract. Relevance.** Dental implants are widely used to restore the patient's teeth. They have become a worthy alternative to removable dentures. With the accumulation of clinical experience, the indications for dental implantation expanded, and as a result, the evaluation of long-term results became possible. In parallel with the expansion of clinical use of dental implants and the introduction of the technology into everyday practice, the experience of complications and errors accumulated, and from single publications in the 1990s, at the very beginning of development, to large-scale studies in the 10s. And if in the early period of implantology development the success of treatment was mainly associated with implant survival, then modern research focuses on the state of tissues around the implant, and the influence of processes in them on the overall outcome of treatment. One of the main complications is inflammation of peri-implant tissues — peri-implantitis. Modern authors define peri-implantitis as an inflammatory process affecting the tissues around a functionally integrated implant, resulting in loss of supporting bone. Continued bone loss around the implant can significantly impair implant stability and function. The authors review the scientific literature describing experimental conservative treatment protocols for peri-implantitis and attempts to achieve osseointegration. **Conclusion.** The reviewed literature advocated various methods of surgical regenerative treatment for peri-implantitis, including the use of bone substitutes, methods of detoxification of implant surfaces, and the administration of antimicrobial agents. There are many different protocols for the treatment of peri-implantitis; they all share the same goal of reducing disease progression and bone loss by eliminating bacterial infection. The controversy over the proper approach to treating peri-implantitis and restoring osseointegration clearly demonstrates the need for more research to answer this question.

**Keywords:** peri-implantitis, conservative treatment of peri-implantitis, osseointegration

**Funding.** The authors received no financial support for the research, authorship and publication of this article.

**Author contribution:** Burlakova L. A. — literature review, text writing, Dymnikov A. B. — preparation and editing of the manuscript. All authors made a significant contribution to the development of the concept, preparation of the article, read and approved the final version before publication.

**Conflict of interest statement.** The authors declare no conflict of interest.

Burlakova L.A., Dymnikov A.B., 2024



This work is licensed under a Creative Commons Attribution 4.0 International License  
<https://creativecommons.org/licenses/by-nc/4.0/legalcode>

**Ethics approval** — not applicable.

**Acknowledgements** — not applicable.

**Consent for publication** — not applicable.

Received 09.10.2023. Accepted 07.02.2024.

**For citation:** Burlakova LA, Dymnikov AB. Techniques for conservative treatment of peri-implantitis. *RUDN Journal of Medicine*. 2024;28(1):57–67. doi: 10.22363/2313–0245–2024–28–1–57–67

## Introduction

Implants are widely used to replace missing teeth [1–4]. The widespread use of implants has also led to the accumulation of experience with complications [5–8]. One of the main complications is inflammation of the peri-implant tissues — peri-implantitis [9–16].

Since the 1982 Toronto (Canada) conference devoted to the problems of morphofunctional interaction between implants and bone tissue recognized the process of osseointegration as the most optimal relationship between the implant surface and bone tissue [3, 11, 17], dental implantation has formed a separate independent financial and knowledge-intensive branch of medicine. For example, according to IData Research as of 2021, the dental implant market in the United States was \$1.1 billion and is projected to grow to \$1.5 billion by 2025 [18]. Domestic market research also notes the growth trend of the dental implant market in the Russian Federation [19]. So according to Discovery Research Group, the volume of the Russian market of dental implants in 2016 was 116 258 thousand dollars, for the first half of 2017 this figure was already 59 920.1 thousand dollars [20].

The analysis of scientific publications for the period from 2010 to 2020 shows the constant improvement of dental implant technologies and the search for ways of development. So the resource <https://pubmed.ncbi.nlm.nih.gov> on a request “dental implant” gives out 2108 publications in 2010, in 2015–3355, in 2020–3404. The bibliographic database of scientific publications in Russia eLibrary also shows a growing interest of Russian scientists in this field of research: from 104 publications in 2010 to 220 in 2019 by the request “dental implantation”.

In parallel with the expansion of clinical application of dental implants and introduction of the technology into daily practice, the experience of complications and errors was also accumulated, from single publications in the 1990s, at the very beginning of development [5–8], to large-scale studies in the 10s [9–14].

In the very first publication that we found in the sources available to us, dated February 1990, researchers from the University of Pennsylvania note the increased concentration of staphylococci and their role in implant rejection [21]. Also in 1990, French clinicians already published an article outlining the objectives of post-implant periodontal treatment, which are limited not only to eliminating the pocket around the implant, but also to creating keratinized attached gingiva around the implant neck and stating the importance of maintaining healthy gums around the implant and preventing the development of gingivitis into peri-implantitis [22].

As clinical experience accumulated, the indications for dental implantation became broader, making it possible to evaluate long-term results. In the early period of implantology, treatment success was mainly associated with implant survival, but modern research focuses on the state of the tissues around the implant and the influence of their processes on the overall treatment outcome [23–26]. It should be noted that from the very first publications and throughout the time of the issue research, peri-implant tissue diseases are quite logically compared with periodontal diseases [27–30], and mostly similarities in etiology and pathogenesis are found, but there are also modern publications, the authors of which question the similarity of mechanisms of these diseases development. Modern authors define peri-implantitis as an inflammatory process that affects the tissues around

a functionally integrated implant, resulting in loss of bone support. Continued bone loss around the implant can significantly impair implant stability and function [31].

Peri-implantitis is treated surgically: removal of the implant, or removal of the cause followed by regenerative therapy to restore the lost bone [32–35].

There are many different ways to antisepticise the implant surface during surgical treatment. For example, with citric acid, delmopinol, chlorhexidine irrigation, air-abrasive powder device, rotating pumice brush, carbon dioxide laser, or gauze/ cotton balls soaked in saline and/or chlorhexidine [36–38]. In addition to the above, autologous bone grafts and bone tissue analogues with or without a membrane may be used to promote osseointegration of the implants [39].

One of the main treatments for peri-implantitis is the regenerative technique, which involves flap lifting, mechanical treatment of the root, and placement of bone graft material with or without a membrane [40, 41]. F. Schwarz studied the treatment of moderate peri-implantitis in 22 patients using nanocrystalline hydroxyapatite (NHA) and natural bone mineral in combination with a collagen membrane [42]. The researchers

followed the patients for two years after treatment and found that there was a significant reduction in the depth of the pocket near the implant.

O.P. Mishler and H. J. Shiau developed an algorithm to help clinicians make decisions about the treatment of peri-implantitis [43]. The algorithm assumes a standard dental implant diameter of 11.5 mm. Patients with shorter implants should be warned about the risk of implant loss due to bone resorption around the implant. The authors suggested conservative treatment for mild peri-implantitis, while regenerative therapy is indicated for moderate to severe peri-implantitis. Based on the proposed methods of treatment of peri-implantitis in the reviewed scientific articles, a scheme of treatment tactics for patients with signs of peri-implantitis was drawn up in Figure 1.

The literature we reviewed advocated various methods for surgical regenerative treatment of peri-implantitis, including the use of bone substitutes, methods of detoxification of implant surfaces, and prescription of antimicrobial agents [44, 45]. This raises an important question: What is the best approach among the various methods of regeneration restoration?

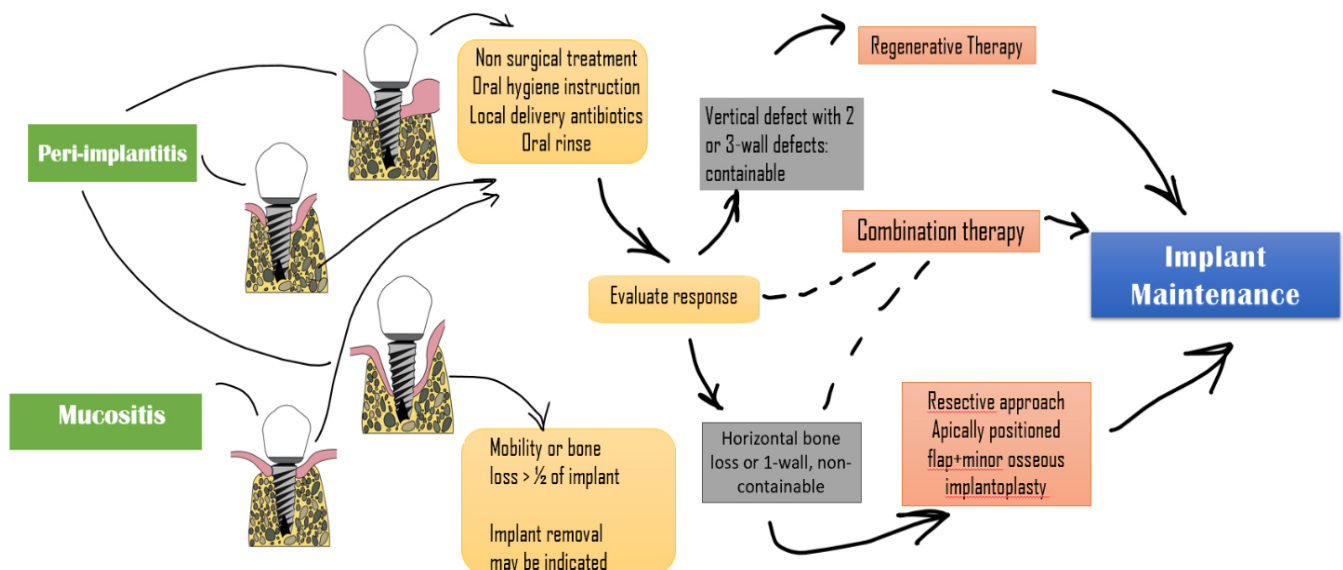


Fig. 1. Summary of peri-implant disease treatment

## Materials and methods

### Search Strategy

The PubMed database was searched electronically for experimental studies including induced peri-implantitis and attempts to achieve osseointegration reinsertion from 1997 to December 2020. A manual search of reference studies in previous articles on a similar topic was also performed.

Inclusion criteria:

1. Studies of induced peri-implantitis in animals (vivo studies).
2. Publications in English only.
3. Attempts or treatments to achieve re- osseointegration.
4. Surgical approaches only.

Exclusion criteria:

1. Studies involving pre-created defects prior to implant placement.
2. studies involving supracrestal implants (partial placement).
3. In vitro and clinical studies.
4. occlusal overload to initiate peri-implantitis.

The search strategy used was as follows: surgical treatment peri implantitis.

The results were combined with a manual search of the bibliographies of all full-text articles and relevant reviews selected from the electronic search.

An initial electronic search yielded 431 article titles. Independent rechecking of these titles and abstracts identified 8 articles that met our criteria for inclusion in this review. The main reasons for exclusion were articles not investigating bone implant contact, reviews, articles dealing with the etiology of peri-implantitis, clinical studies, lack of histologic findings, case reports, and surgically created peri-implantitis defects.

This review focused on the surgical treatment of peri-implantitis, thus all studies included open flap surgery to degranulate and mechanically treat infected implant surfaces and resulting bone defects. Several methods of decontamination of infected implant surfaces were evaluated.

## Results and discussion

### Antiseptic surface treatment

#### *Chemicals*

Several chemical solutions (liquids) for decontamination of infected or exposed implant surfaces have been tested. S. Schou and colleagues compared the surface cleansing ability of air-force abrasive block, citric acid, chlorhexidine, and saline; the results showed no significant difference [46–48]. Similar results were obtained in a study by L. G. Persson and colleagues, in which a combination of CO<sub>2</sub> laser and H was used in comparison with the use of cotton balls moistened with physiological solution [49]. It was stated that the simplest method of implant surface cleaning with gauze moistened alternately with chlorhexidine and saline was preferred for implant surface preparation in the surgical treatment of peri-implantitis. T. M. You and colleagues used gauze soaked alternately in chlorhexidine and saline, whereas F. Schwarz and colleagues used cotton balls soaked in saline and irrigation with saline [17, 50].

The study of L. Sennerby and colleagues used cotton balls soaked in saline to clean the contaminated implant surface, but their study was to analyze the use of resonance frequency techniques to detect bone-to-implant contact [51]. A Parlar and colleagues used specially designed implants that consisted of a basal part and a replaceable intraosseous implant cylinder (EIIC) to remove the infected and disintegrated implant part and sterilize it outside the oral cavity or replace it with a new implant part [52]. The purpose of this experiment was to evaluate different decontamination methods and implant surface configurations for the re- osseointegration of contaminated dental implants. The results did not prove the advantages of replacing EIIC with new or cleaned in situ by spraying saline solution under pressure for 3 minutes.

S.Y. Park and colleagues used Aqua-pikVR (Aqua-pik, Seoul, Korea) at high pressure (1200 pulses/min) and SuperflossVR thread (P&G, Cincinnati, Ohio) impregnated with chlorhexidine to decontaminate exposed surfaces treated with alumina and acid [53]. E.E. Machtei and colleagues used 24% EDTA after open flap debridement to decontaminate the surface

of thirty implants [54]. M. Htet and colleagues used citric acid to decontaminate the implant surface [55].

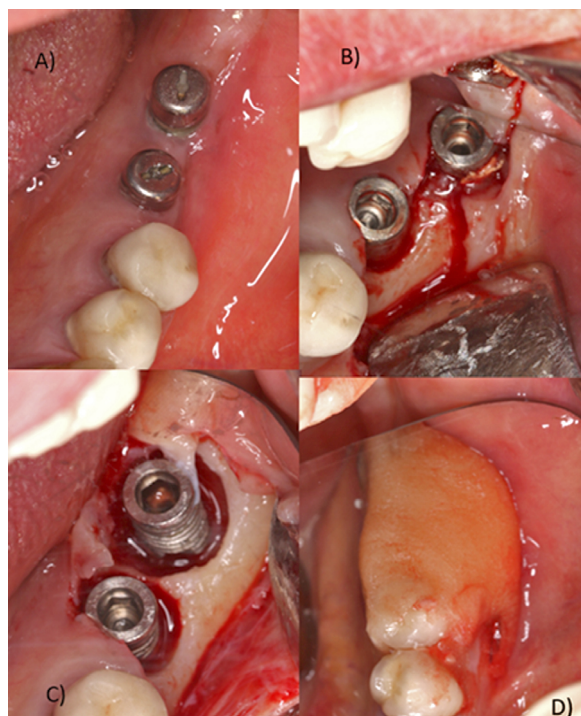
### Mechanical method

Surgical treatment of peri-implantitis includes flap or open access surgery. Along with the previously mentioned techniques, the authors performed sanitation of the infected implant surface by several methods, from curettes to lasers. Debridement of granulation tissues and cleaning of the implant surface are important steps, thanks to which regeneration or even reintegration can be achieved. S. Schou and colleagues used a combination of flap surgery, citric acid irrigation and saline solution to decontaminate the surface, resulting in the highest re-integration rate (46%) compared to other study groups [46–48]. S. Stübinger and colleagues used CO<sub>2</sub> laser, air-powder abrasive and their combination to decontaminate titanium plasma implants in 6 dogs [56]. The results showed that the CO<sub>2</sub> laser alone (0.69%)

or in combination with air-powder abrasive (0.77%) was effective.

In the study by F. Schwarz and colleagues, implantoplasty was the method of choice. The experimental study was conducted on beagle dogs [57]. The sites of intraosseous defects were filled with particles of bone-plastic material of natural bovine origin.

Smoothing and polishing of the implant area was performed after cleaning the infected implant surface with cotton balls moistened with physiological solution. Diamond burs and Arkansas stones were used under abundant irrigation with sterile saline solution. It was concluded that implantoplasty is a safe and effective treatment for the supracrestal peri-implant defect. The importance of polishing the implant surface is illustrated in Figure 2. This figure shows the accumulation of plaque stones, after cleaning which the implant surface was polished.



**Fig. 2** Four treatment options were randomly distributed among the implants.

- A) Granulation tissue removal and surface debridement were performed using curettes; B) for surface debridement, CPS was homogeneously applied to all exposed areas of the implant surface and all remaining soft plaque was removed under moderate pressure; C) followed by thorough irrigation with sterile saline. Implantoplasty was performed around the implants; D) the experimental sites were left closed for healing for 12 weeks, modified [57].

Laser therapy has also been considered in some studies [50, 58–60]. Laser therapy is becoming increasingly common in dentistry. For example, photodynamic therapy (PDT), which works by using a low-density laser beam with a photosensitizer, targets specific cells, causing permanent cell damage. A study by JA Shibli et al used PDT using a GaAlAs diode laser and toluidine blue O as a photosensitizer to target bacteria and clean the implant surface after induced peri-implantitis [58].

Some studies have used laser devices to clean the infected implant surface without using a photosensitizer. L.G. Persson and colleagues evaluated the use of laser together with continuous activation of hydrogen peroxide solution [49].

F. Schwarz and colleagues used a YAG laser to study peri-implantation wound healing in comparison with a plastic curette with a gel containing metronidazole and an ultraviolet device in which energy from vertical vibration of the instrument was transmitted to the implant surface, tissues around the implant, and suspensions of hydroxyapatite particles and water [60]. As a result, the best result was observed for the Er: YAG laser, which was 44.8%. M Htet et al used the Er: YAG laser (wavelength 2.940 nm, 100 MJ/pulse, 10 Hz) for surface decontamination of anodized surface implants compared with PDT using a GaAlAs diode laser (830-nm, 50 MW, 4 J/cm<sup>2</sup>) versus a titanium drill (1 mm diameter round tip) at 800 rpm with plenty of irrigation with saline for 2 minutes [55].

Their results showed that the combined mechanical and chemical treatment (titanium drill with citric acid group) resulted in significantly greater vertical bone height than the other groups and significantly improved bone to implant contact (22.81% ± 14.45%) than the Er: YAG (13.76% ± 17.23%), PDT (2.7% ± 5.85%) and bur groups (8.09% ± 12.15%).

### **Regenerative therapy**

The goal of all peri-implantitis treatments is to achieve osseointegration on the previously contaminated implant surface. After removal of granulation tissue and elimination of bacterial biofilm, several osseointegration techniques have been evaluated using bone substitutes or

bone graft\without a membrane. After surgical treatment of peri-implantitis, several methods have been tried by a number of investigators to promote osseointegration re-integration [46–48, 58, 59]. As a rule, they varied with or without using a membrane together, with or without a bone graft or bone substitutes.

S. Schou and colleagues performed 3 experiments on the surgical treatment of peri-implantitis. In the first 2 they studied an expanded polytetrafluoroethylene (ePTFE) membrane with an autologous bone graft and an ePTFE membrane with bio-Oss [46–48]. It is concluded that autogenous bone graft or bone substitutes (Bio-Oss) with ePTFE membrane was the best combination for reintegration. However, in the autologous bone graft group, reintegration was 45%, whereas in the Bio-Oss group it was 36%.

In another experiment analyzing 4 different strategies for antiseptic treatment of the implant surface, an autologous bone graft and an ePTFE membrane were used. The autogenous bone graft with ePTFE membrane, by its insignificant result, can promote a significant degree of osseointegration regardless of the surface disinfection methods.

The authors concluded that treatment with photosensitization could lead to significant bone repair with osseointegration re-integration. Later, they conducted another study in which they compared a mechanical treatment method with photosensitization and a mechanical treatment without photosensitization [58]. The results coincided with their previous study.

In addition, the study by Persson and colleagues used only flap surgery in combination with surface disinfection procedures [49]. They suggested that a contaminated surface does not prevent osseointegration, at least not in implants with a rough surface. They explained that the lack of significant results may indicate that surface characteristics are important for osseointegration reintegration.

Although it is impossible to assess the extent to which bacterial colonization in the implant area may have influenced bone regeneration and the subsequent establishment of new bone-implant contact, the Er: YAG laser promoted osseointegration.

In a study by T.M. You and colleagues, an autologous bone graft, with and without platelet-enriched fibrin, was tested after cleaning the contaminated implant surface with gauze soaked alternately in 0.1% chlorhexidine aqueous solution and physiological solution [17]. Repeated osseointegration (50.1%) was observed in the group treated with autologous bone graft in combination with platelet-enriched fibrin without using a membrane.

In the studies of L.G. Persson et al. and F. Schwarz and colleagues a layer of connective tissue appeared between the implant surface and the bone [50, 60]. The common fact is that these studies did not use a collagen membrane, which is usually used to prevent the growth of connective tissue and epithelium in peri-implant bone defects.

The S.Y. Park and colleagues study treated peri-implantitis with flap elevation in combination with three treatment modalities: Hydroxyapatite particles mixed with collagen gel (control group, n = 8), hydroxyapatite particles mixed with collagen gel containing autologous periodontal ligament stem cells (PDLSCs) (PDLSC group, n = 8) and hydroxyapatite particles with collagen gel containing BMP-2-expressing autologous PDLSCs (bone morphogenetic protein 2/PDLSC group, n = 8) [61].

In group 2/PDLSC, the histological results showed a significantly greater amount of osseointegration of the bone (2.1 mm). However, there were no significant differences between the groups with regard to the new contact with the bone implant.

For the regenerative procedure, E.E. Machtei and colleagues used beta-tricalcium phosphate (b-TCP) coated with resorbable membrane and injected with endothelial progenitor cells (EPC) loaded on b-TCP and coated with resorbable membrane and compared with the group without grafting [54].

The EPC group had a shorter distance to the first BIC ( $3.29 \pm 0.69$  mm) compared to  $4.2 \pm 0.92$  mm (b-TCP) and  $3.82 \pm 0.73$  mm (mechanical implant surface cleaning (dibredge) with open flap). Mean histologic BIC was 2–3 times higher in the EPC group ( $17.65\% \pm 3.3\%$ ) compared with open flap debridement ( $7.55\% \pm 2.24\%$ ,  $P = 0.01$ ) and b-TCP ( $5.68\% \pm 2.91\%$ ,  $P = 0.05$ ). BIC greater than 25% was found only in the EPC group.

## Conclusion

Since implantation is used more and more frequently every year, the number of complications is increasing. The increase in publications every year corresponds to the constant interest of researchers in the topic. The search for optimal treatment methods for peri-implantitis is ongoing. In this topic, methods of antiseptic treatment of the implant surface used either separately or simultaneously with and without directed bone regeneration were reviewed.

Despite the fact that in most cases flap surgery was performed, it is noted that, for the best treatment outcome, repeated antiseptic treatment by chemical or mechanical means is necessary. With regard to implant surfaces, the best osseointegration was observed with roughened implant surfaces combined with guided bone regeneration.

Treatment of peri-implantitis is unpredictable, but surgical treatment combined with chemical and mechanical antiseptic treatment of the implant surface may be considered the most reliable treatment. Laser therapy is a relatively new method of treatment that needs more research to determine the best laser parameters to use.

Currently, there is no consensus on the etiology of peri-implantitis, and new ways and approaches to prevent and treat this disease are still being sought.

## References/ Библиографический список

1. Pjetursson BE, Thoma D, Jung R, Zwahlen M, Zembic AA. Systematic review of the survival and complication rates of implant-supported fixed dental prostheses (FDPs) after a mean observation period of at least 5 years. *Clin Oral Implants Res*. 2012;23:22. doi:10.1111/j.1600-0501.2012.02546.x
2. Lang NP, Pjetursson BE, Tan K. A systematic review of the survival and complication rates of fixed partial dentures (FPDs) after an observation period of at least 5 years: II. Combined tooth-implant-supported FPDs. *Clin Oral Implants Res*. 2004;15:643. doi:10.1111/j.1600-0501.2004.01118.x
3. Albrektsson T, Donos N, Working G. Implant survival and complications. The Third EAO consensus conference 2012. *Clin Oral Implants Res*. 2012;23:63. doi:10.1111/j.1600-0501.2012.02557.x
4. Srinivasan M, Vazquez L, Rieder P. Survival rates of short (6 mm) micro-rough surface implants: a review of literature and meta-analysis. *Clin Oral Implants Res*. 2014;25:539. doi:10.1002/JPER.16-0350

5. Meffert RM. Periodontitis and periimplantitis: one and the same? *Pract Periodontics Aesthet Dent.* 1993;5(9):79. doi:10.18821/0869-2106-2019-25-5-324-327
6. Bower RC, Ann R. Peri-implantitis. *Australas Coll Dent Surg.* 1996;13:48. doi:10.1002
7. Forna N, Burlui V, Luca IC, Indrei A. Peri-implantitis. *Rev Med Chir Soc Med Nat Iasi.* 1998;102(3-4):74.
8. Mombelli A. Etiology, diagnosis, and treatment considerations in peri-implantitis. *Curr Opin Periodontol.* 1997;4:127. doi:10.1111/j.1600-0757.1998.tb00124.x
9. Jordana F, Susbielles L, Colat-Parros J. Periimplantitis and Implant Body Roughness: A Systematic Review of Literature. *Implant Dent.* 2018;27(6):672. doi: 10.1097/ID.0000000000000834.
10. Pesce P, Canullo L, Grusovin MG, de Bruyn H, Cosyn J, Pera P. Systematic review of some prosthetic risk factors for periimplantitis. *J Prosthet Dent.* 2015;114(3):346. doi: 10.1016/j.prosdent.2015.04.002.
11. Belibasakis GN, Manoil D. Microbial Community-Driven Etiopathogenesis of Peri-Implantitis. *J Dent Res.* 2021;100(1):21-28. doi:10.1177/0022034520949851.
12. Berglundh T, Jepsen S, Stadlinger B, Terheyden H. Peri-implantitis and its prevention. *Clin Oral Implants Res.* 2019;30(2):150-155. doi: 10.1111/clr.13401
13. Kopetsky IS, Strandstrem EB, Kopetskaya AI. Modern aspects of periimplantitis treatment methods. *Medical Journal of the Russian Federation.* 2019;25(5):324. (in Russian). doi:10.18821/0869-2106-2019-25-5-6-324-327 [Копецкий, И.С., Страндстрем Е.Б., Копецкая А.И. Современные аспекты методов лечения периимплантитов // Российский медицинский журнал. 2019. Т. 25. вып. 5-6. С. 324-327]
14. Potrivailo A, Prikuls VF, Amkhadova MA, Prikule DV, Aleskerov E. Modern ideas about the prevention and treatment of periimplantitis: a literature review. *Medical alphabet.* 2020;1(12):8. (In Russian). doi:10.33667/2078-5631-2020-12-8-11 [Потривайло А., Прикул В.Ф., Амхадова М.А. и др.] Современное представление о профилактике и лечении периимплантита: обзор литературы // Медицинский алфавит. 2020. № 12. С. 8-11]
15. Dzhafarov EM, Edisherashvili UB, Dolgalev AA. Prospects for the use of probiotics in the treatment of peri-implantitis. Literature review. *Medical alphabet.* 2022;2:7. (In Russian). doi:10.33667/2078-5631-2022-2-7-10 [Джафаров Э.М., Эдишерашвили У.Б., Долгалева А.А. Перспективы применения пробиотиков при лечении периимплантита. Обзор литературы // Медицинский алфавит. 2022., вып 2. С. 7-10].
16. Singh P. Understanding peri-implantitis: A strategic review. *J Oral Implantol.* 2011;37:622. doi: 10.1563/AAID-JOI-D-10-00134
17. You TM, Choi BH, Zhu SJ. Treatment of experimental peri-implantitis using autogenous bone grafts and platelet-enriched fibrin glue in dogs. *Oral Surg Oral Med Oral Pathol Oral Radiol Endod.* 2007;103:34. doi:10.1016/j.tripleo.2006.01.005
18. Dental Implants Market Size, Share & COVID19 Impact Analysis. United States. 2021-2027. MedSuite. Includes: Dental Implants (Premium, Value, Discount, Mini), Final Abutments (Stock, Custom Cast, CAD/CAM), Dental Implant Instrument Kits, Treatment Planning Software & Surgical Guides. 2021;285 U.S. Dental Implants Market & COVID19 Impact | 2021-2027 (idataresearch.com)
19. Discovery research group. Analysis of the dental implants market in Russia. 2018;82. (In Russian). [Анализ рынка стоматологических имплантов в России. 2018;82]. Дата обращения: 10 August 2023. <https://marketing.rbc.ru/research/27962/>
20. Zarb G. Proceedings of the Toronto conference on osseointegration in clinical dentistry. *Morsby: St. Louis.* 1983;89. doi:10.1016/0022-3913(90)90237-7
21. Rams TE, Feik D, Slots J. Staphylococci in human periodontal diseases. *Oral Microbiol Immunol.* 1990;5(1):29. doi: 10.1111/j.1399-302x.1990.tb00222.x
22. Saadoun AP. Imperatifs parodontaux en implantologie ostéointégrée et bio-intégrée. *Periodontal requirements in osseointegrated and biointegrated implantology.* 1990;(71):126. doi: 10.1111/j.1600-051x.1995.tb00123.x
23. Renvert S, Giovagnoli JL, Ostrovsky A. The ABC. 2014. 255 p. (In Russian). [Стефан Ренверт, Жан-Луи Джованьоли; пер. Александр Островский; Азбука, 2014. 255 с.]
24. Sirak SV, Didenko MO, Sirak AG, Shchetinina EE, Sirak ES, Pogozheva AV, Petrosyan GG, Lenev VN. Influence of load on modeling and remodeling of bone tissue in experimental perimplantitis. *Medical News of North Caucasus.* 2020;15(3):364-369. (In Russian). doi 10.14300/mnnc.2020.15086 [Сирак С.В., Диденко М.О., Сирак А.Г. и др. // Влияние нагрузки на процессы моделирования и ремоделирования костной ткани при экспериментальном периимплантите // Медицинский вестник Северного Кавказа. 2020. вып. 3. С. 364-368.]
25. Shevela TL, Pohodenko-Chudakova IO, Kabak SL. Experimental and morphological substantiation of the differentiated approach to the treatment of peri-implantitis. *Collection of III All-Russian scientific-practical conference with international participation, Kirov, April 05-06, 2019. Edited by L.M. Zheleznova. Kirov: Kirov State Medical University of the Ministry of Health of the Russian Federation.* 2019: 255-257. (In Russian). [Шевела Т.Л., Походенько-Чудакова И.О., Кабак С.Л. // Морфологические изменения костной ткани в процессе развития периимплантита при избыточной нагрузке на имплантат // Актуальные вопросы стоматологии: сборник III Всероссийской научно-практической конференции с международным участием, Киров, 05-06 апреля 2019 года / под ред. Л.М. Железнова. — Киров: Федеральное государственное бюджетное образовательное учреждение высшего образования «Кировский государственный медицинский университет» Министерства здравоохранения Российской Федерации, 2019. С. 255-257].
26. Bogacheva NV, Tuneva NA, Comparative assessment of microbioma in patients with periimplantitis and periodontitis. *Problems in medical mycology.* 2021;23(2):57. (In Russian). [Богачева Н.В., Тунева Н.А. // Сравнительная оценка микробиома у пациентов с периимплантитами и пародонтитами // Проблемы медицинской микологии. 2021. 23. вып. 2. С. 57.]
27. Meffert RM. Periodontitis vs. peri-implantitis: the same disease? The same treatment? *Crit Rev Oral Biol Med.* 1996;7(3):278. doi: 10.1177/10454411960070030501
28. Soehren SE. Similarities between the development and treatment of plaque-induced peri-implantitis and periodontitis. *J Mich Dent Assoc.* 1996;78(3):32. doi: 10.1007/BF02493289
29. Berglundh T, Zitzmann NU, Donati M. Are peri-implantitis lesions different from periodontitis lesions? *J Clin Periodontol.* 2011;38(11):188. doi: 10.1111/j.1600-051X.2010.01672.x



30. Sgolastra F, Petrucci A, Severino M, Gatto R, Monaco A. Periodontitis, implant loss and peri-implantitis. A meta-analysis. *Clin Oral Implants Res*. 2015. doi:10.1111/clr.12319
31. Lang NP, Berglundh T. Working Group 4 of Seventh European Workshop on Periodontology. Periimplant diseases: Where are we now? Consensus of the Seventh European Workshop on Periodontology. *J Clin Periodontol*. 2011;38:178. doi: 10.1111/j.1600-051X.2010.01674.x
32. Chvartzaid D, Koka S. On manufactured diseases, healthy mouths, and infected minds. *Int J Prosthodont*. 2011;24:102. doi: 10.1016/j.prosdent.2015.04.002
33. Koka S, Zarb G. On osseointegration: The healing adaptation principle in the context of osseosufficiency, osseoseparation, and dental implant failure. *Int J Prosthodont*. 2012;25:48.
34. Schwarz F, Bieling K, Latz T, Nuesry E, Becker J. Healing of intrabony peri-implantitis defects following application of a nanocrystalline hydroxyapatite (Ostim) or a bovine-derived xenograft (Bio-Oss) in combination with a collagen membrane (Bio-Gide). A case series. *J. Clin. Periodontol.*, 2006;33:491. doi: 10.1111/j.1600-051X.2006.00936.x
35. Subramani K, Wismeijer D. Decontamination of titanium implant surface and re- osseointegration to treat peri-implantitis: A literature review. *Int J Oral Maxillofac Implants*. 2011;27:1043.
36. Wetzel AC, Vlassis J, Caffesse RG. Attempts to obtain re-osseointegration following experimental peri-implantitis in dogs. *Clin Oral Implants Res*. 1999;10:111. doi:10.1034/j.1600-0501.1999.100205.x
37. Persson LG, Ericsson I, Berglundh T. Osseointegration following treatment of peri-implantitis and replacement of implant components. An experimental study in the dog. *J Clin Periodontol*. 2001;28: 258. doi:10.1097/ID.0000000000000712
38. Persson LG, Berg Lundh T, Lindhe J. Re-osseointegration after treatment of peri-implantitis at different implant surfaces. An experimental study in the dog. *Clin Oral Implants Res*. 2001;12:595. doi:10.1034/j.1600-0501.2001.120607.x
39. Hürzeler MB, Quiñones CR, Schüpback P. Treatment of peri-implantitis using guided bone regeneration and bone grafts, alone or in combination, in beagle dogs. Part 2: Histologic findings. *Int J Oral Maxillofac Implants*. 1997;12:168. doi:10.14436/2237-650X.8.3.058-063.oar
40. Ramanauskaite A, Daugela P, Faria DE, Almeida DE, Saulacic N. Surgical non-regenerative treatments for peri-implantitis: a systematic review. *J. Oral. Maxillofac. Res*. 2016;7:14 doi: 10.5037/jomr.2016.7314
41. Nguyen-Hieu T, Borghetti A, Aboudharam G. Peri-implantitis: from diagnosis to therapeutics. *J. Investig. Clin. Dent.*, 2012;3:79. doi: 10.1111/j.2041-1626.2012.00116.x
42. Schwarz F, Bieling K, Latz T, Nuesry E, Becker J. Healing of intrabony peri-implantitis defects following application of a nanocrystalline hydroxyapatite (Ostim) or a bovine-derived xenograft (Bio-Oss) in combination with a collagen membrane (Bio-Gide). A case series. *J. Clin. Periodontol.*, 2006;33:491. doi:10.1111/j.1600-051X.2006.00936.x
43. Mishler OP, Shiau HJ. Management of peri-implant disease: a current appraisal. *J. Evidence Based Dent. Pract*. 2014;14:53. doi:10.1016/j.jebdp.2014.04.010
44. Hussain RA, Miloro M, Cohen JB. An Update on the Treatment of Periimplantitis. *Dent Clin North Am*. 2021;65(1):43. doi:10.1016/j.cden.2020.09.003.
45. Wang CW, Renvert S, Wang HL. Nonsurgical Treatment of Periimplantitis. *Implant Dent*. 2019;28(2):155-160. doi:10.1097/ID.0000000000000846.
46. Schou S, Holmstrup P, Jørgensen T. Autogenous bone graft and ePTFE membrane in the treatment of peri-implantitis. II. Stereologic and histologic observations in cynomolgus monkeys. *Clin Oral Implants Res*. 2003;14:404. doi:10.1034/j.1600-0501.2003.120909.x
47. Schou S, Holmstrup P, Jørgensen T. Anorganic porous bovine-derived bone mineral (Bio-Oss®) and ePTFE membrane in the treatment of peri-implantitis in cynomolgus monkeys. *Clin Oral Implants Res*. 2003;14:535. doi:10.1034/j.1600-0501.2003.00911.x
48. Schou S, Holmstrup P, Jørgensen T. Implant surface preparation in the surgical treatment of experimental peri-implantitis with autogenous bone graft and ePTFE membrane in cynomolgus monkeys. *Clin Oral Implants Res*. 2003;14:412. doi:10.1034/j.1600-0501.2003.00912.x
49. Persson LG, Ericsson I, Berglundh T. Osseointegration following treatment of peri-implantitis and replacement of implant components. An experimental study in the dog. *J Clin Periodontol*. 2001;28: 258. doi:10.1034/j.1600-051x.2001.028003258.x
50. Shibli JA, Martins MC, Ribeiro FS. Lethal photosensitization and guided bone regeneration in treatment of peri-implantitis: An experimental study in dogs. *Clin Oral Implants Res*. 2006;17:273. doi:10.1111/j.1600-0501.2005.01167.x
51. Sennerby L, Persson LG, Berglundh T. Implant stability during initiation and resolution of experimental periimplantitis: An experimental study in the dog. *Clin Implant Dent Rel Res*. 2005;7:136. doi:10.1111/j.1708-8208.2005.tb00057.x
52. Parlar A, Bosshardt DD, Çetiner D. Effects of decontamination and implant surface characteristics on re-osseointegration following treatment of periimplantitis. *Clin Oral Implants Res*. 2009;20:391. doi:10.1111/j.1600-0501.2008.01655.x
53. Park SY, Kim KH, Gwak EH. Ex vivo bone morphogenetic protein 2 gene delivery using periodontal ligament stem cells for enhanced re-osseointegration in the regenerative treatment of peri-implantitis. *J Biomed Mater Res A*. 2015;103:38. doi:10.1002/jbm.a.35145
54. Machtei EE, Kim DM, Karimbux N. The use of endothelial progenitor cells combined with barrier membrane for the reconstruction of periimplant osseous defects: An animal experimental study. *J Clin Periodontol*. 2016;43:289. doi:10.1111/jcpe.12511
55. Htet M, Madi M, Zakaria O. Decontamination of anodized implant surface with different modalities for peri-implantitis treatment: Lasers and mechanical debridement with citric acid. *Periodontol*. 2016;87:953. doi:10.1902/jop.2016.150615
56. Stübinger S, Henke J, Donath K. Bone regeneration after peri-implant care with the CO<sub>2</sub> laser: A fluorescence microscopy study. *Int J Oral Maxillofac Implants*. 2005;20:203. doi: 10.1007/s10103-012-1215-z
57. Schwarz F, Sahn N, Mihatovic I. Surgical therapy of advanced ligature-induced peri-implantitis defects: Cone-beam computed tomographic and histological analysis. *J Clin Periodontol*. 2011;38:939. doi:10.1111/j.1600-051X.2011.01739.x

58. Shibli JA, Martins MC, Ribeiro FS. Lethal photosensitization and guided bone regeneration in treatment of peri-implantitis: An experimental study in dogs. *Clin Oral Implants Res.* 2006;17:273. doi:10.1111/j.1600-0501.2005.01167.x

59. Shibli JA, Martins MC, Nociti FH Jr. Treatment of ligature-induced peri-implantitis by lethal photosensitization and guided bone regeneration: A preliminary histologic study in dogs. *J Periodontol.* 2003;74:338. doi:10.1902/jop.2003.74.3.338


60. Schwarz F, Jepsen S, Herten M. Influence of different treatment approaches on non-submerged and submerged healing of ligature

induced peri-implantitis lesions: An experimental study in dogs. *J Clin Periodontol.* 2006;33:584. doi:10.1111/j.1600-051X.2006.00956.x

61. Park SY, Kim KH, Gwak EH. Ex vivo bone morphogenetic protein 2 gene delivery using periodontal ligament stem cells for enhanced re-osseointegration in the regenerative treatment of peri-implantitis. *J Biomed Mater Res A.* 2015;103:38. doi:10.1002/jbm.a.35145

## Методы консервативного лечения периимплантита

Л.А. Бурлакова  , А.Б. Дымников 

Российский университет дружбы народов, г. Москва, Российская Федерация  
 shererrrr9@gmail.com

**Аннотация.** Актуальность. Дентальные имплантаты получили широкое применение для восстановления зубных рядов у пациента. Они стали достойной альтернативой съемным протезам. По мере накопления клинического опыта, ширились показания к дентальной имплантации, в результате чего стала возможной оценка отдаленных результатов. Параллельно с расширением клинического применения дентальных имплантатов и внедрением технологии в повседневную практику, накапливался и опыт осложнений и ошибок, и от единичных публикаций в 1990-х гг., в самом начале развития, до масштабных исследований в 10-х. И если в раннем периоде развития имплантологии успех лечения связывали в основном с выживаемостью имплантатов, то современные исследования фокусируются на состоянии тканей вокруг имплантата, и влиянию процессов в них на общий исход лечения. Одно из основных осложнений — воспаление периимплантных тканей — периимплантит. Современные авторы определяют периимплантит как воспалительный процесс, поражающий ткани вокруг функционально интегрированного имплантата, что приводит к потере опорной кости. Продолжающаяся потеря костной ткани вокруг имплантата может значительно ухудшить стабильность и функцию имплантата. Рассмотрена научная литература, в которой описываются протоколы экспериментального консервативного лечения периимплантита и попытки добиться повторной остеоинтеграции. **Выводы.** В рассмотренной научной литературе пропагандировались различные методы хирургического регенеративного лечения периимплантита, включая использование заменителей кости, методы детоксикации поверхностей имплантатов, назначения противомикробных препаратов. Существует множество различных протоколов лечения периимплантита; все они объединены одной целью — снижение прогрессирования заболевания и потери костной ткани путем устранения бактериальной инфекции. Споры относительно правильного подхода к лечению периимплантита и восстановлению остеоинтеграции, очевидно, демонстрируют потребность в более расширенных исследованиях для ответа на этот вопрос.

**Ключевые слова:** периимплантит, консервативное лечение периимплантита, остеоинтеграция

**Информация о финансировании.** Авторы заявляют об отсутствии внешнего финансирования.

**Вклад авторов.** Бурлакова Л.А. — обзор литературы, написание текста. Дымников А.Б. — подготовка и редактирование рукописи. Все авторы внесли существенный вклад в разработку концепции, подготовку статьи, прочли и одобрили финальную версию перед публикацией.

**Информация о конфликте интересов.** Авторы заявляют об отсутствии конфликта интересов.

**Благодарности** — неприменимо.

**Этическое утверждение** — неприменимо.

**Информированное согласие.** Неприменимо.

Поступила 09. 10. 2023. Принята 07. 12. 2023.

**Для цитирования:** *Burlakova L.A., Dymnikov A.B.* Techniques for conservative treatment of peri-implantitis. *RUDN Journal of Medicine*. 2024;28(1):57–67. doi: 10.22363/2313–0245–2024–28–1–57–67

*Corresponding author:* Burlakova Lyubov Aleksandrovna — PhD student, Department of Oral and Maxillofacial Surgery, Institute of Medicine, RUDN University, 117198, Miklukho- Maklaya str., 6, Moscow, Russian Federation. E-mail: shererrrr9@gmail.com  
Burlakova L.A. ORCID 0000–0002–5321–3304  
Dymnikov A.B. ORCID 0000–0001–8980–6235

*Ответственный за переписку:* Бурлакова Любовь Александровна — аспирант, кафедра челюстно-лицевой хирургии и хирургической стоматологии, медицинский институт РУДН, Российская Федерация, 117198, г. Москва, ул. Миклухо-Маклая, д. 6. E-mail: shererrrr9@gmail.com  
Бурлакова Л.А. SPIN 1109–6468; ORCID 0000–0002–5321–3304  
Дымников А.Б. SPIN 7254–4306; ORCID 0000–0001–8980–6235