

ЭКСПЕРИМЕНТАЛЬНАЯ ФИЗИОЛОГИЯ

DOI: 10.22363/2313-0245-2018-22-1-120-126

CHANGES IN RABBITS' LIVER MORPHOLOGICAL PARAMETERS IN SIMULATION OF HYPOXIA CORRECTED BY THE USE OF THE MODIFIED ISOTOPIC D/H COMPOSITION IN THE WATER

M.I. Bykov^{1,2}, M. Chikhladze³, V.V. Shchava², A.A. Elkina⁴, I.M. Bykov¹,
K.A. Popov¹, A.V. Moiseev⁵, M.G. Baryshev⁴

¹Kuban state medical university, Krasnodar, Russia;

²Scientific research institute of the Ochapovsky regional clinic
of Ministry of Health of the Russian Federation, Krasnodar, Russia;

³National Institute of Allergology, Asthma and Clinical Immunology
of Georgian National Academy of Science, Tskhaltubo, Georgia;

⁴Kuban state university, Krasnodar, Russia;

⁵Kuban state agrarian university, Krasnodar, Russia

Abstract. The aim of the research was to study the effect of the water menu with a low D/H on morphological hepatocytes parameters in rabbits in modeling of an acute hypoxic liver damage. **Methods:** morphological research of liver tissues of the experimental animals had been done by cytological and histological methods, which had been prepared impression smear of the studying organ after which it had been stained with azur-eosin according to a common procedure; the blood plasma had been done by the pulsing nuclear magnetic resonance spectrometer JEOL JNM-ECA 400MHz, evaluate an isotopic composition of rat lyophilized liver tissues had been used an isotopic mass-spectrometer DELTA^{plus}.

Results: There are the statistics presented in the given study reveal the feature of the water menu with the low deuterium concentration decreases the liver tissue damage in hypoxia simulating by the compression of a hepatoduodenal ligament. It was demonstrated that the use of the deuterium depleted water (DDW) reliably decreases the deuterium concentration in a blood plasma (by 32%) and in liver tissue (by 9%), which shows the effectiveness of the correlation of isotopic composition of internal environment and organs by the products with the low deuterium concentration.

Conclusion: It has been established that the use of the DDW as a hepatoprotective measure is equal in its effectiveness to some of lipophilic antioxidants. This allows to use vegetative antioxidant factors and a water menu with a low deuterium concentration (40 ppm) as a combined measure, in order to correct morphological liver defects in its ischemic damage.

Key words: deuterium, liver, rabbits, morphology, hypoxia

Correspondence Author:

Mikhail Ilyitch Bykov M.D., Ph.D., Associate Professor of the Department of Surgery №1, State Educational Institution of Higher Professional Learning “The Kuban State Medical University” of the Ministry of Public Health of Russia, physician in chief of the Department of Endoscopy № 2, State Educational Institution of Learning “Scientific Research Institute of the Ochapovsky Regional Clinic” of the Ministry of Public Health of Russia. E-mail: bikov_mi@mail.ru

INTRODUCTION

A multiple factor of liver damage pathogenesis requires the liver protection on various levels, which determines the research of new hepatoprotectors. It is

known that the functioning of an organism, the organs and tissues condition, environment adaptation potency, and an ability reserve to neutralize harmful xenobiotics are mostly determined by the quality of

consumed products. Liver is the major organ in the sustention of a biochemical homeokinesis in an organism as it takes part in a protein, lipid, carbohydrate and pigment metabolism. In this regard the problem of studying the molecular regulating mechanisms of the liver functional activity and its metabolic adaptation to toxic agents exposure is still a significant direction in a modern experimental and clinical hepatology [1, 2]. In preventive and complex therapy of hepatic diseases there antioxidant medications are popular, they improve an organism resistance to hypoxic conditions, stabilize hepatocytes sarcolemma in the condition of peroxidation process activation, limit transmembrane calcium ions transfer from an intercellular space [3, 4]. The usage of the nutritional correction is one of the available approach to improve a measure effectiveness in the correcting of morpho-functional liver condition.

In addition to traditional antioxidant medications, one of the perspective nutrient materials for the correction of an antioxidant organism potency is the deuterium depleted water (DDW). According to the data from scientific literature water with the low deuterium level in an organism with pathologic processes can decrease the concentration of non-radioactive isotops, and reduce intoxication by the increase of adaptation potency [5]. Water with low deuterium intervanted to the water menu of the laboratory animals changes the isotopic metabolism rate, and this has an effect on the thermokinetic and thermodynamic biomolecules parameters, accelerating biochemical processes depending on an isotopic composition of enzymes and coenzymes [6]. These kind of change, connected with an isotopic metabolism reaction, can increase the adaptation potency of an organism by a stimulating of protection systems (antioxidant, for example) [7—9], and this can be used in a complex therapy of hepatic diseases.

Some specialists say that the changes of morphological parameters of internal organs are more of an informative character comparing with their changes in blood [10, 11], and are more sensitive to local changes in an organism in hypoxia and should be investigated further. However, in scientific litera-

ture today there are not enough information about changes in hepatocytes at the DDW usage, and this aspect of a metabolic correction needs to be studied. That is why the research of the new and more effective hepatoprotectors with evident antioxidant features [12—16] is actual today.

It is also known that hypoxia is accompanied by an activation of a biomolecules peroxidation which is caused by an increase of free radicals production which lead to cells and their organelles damage [17—19]. An enzymatic component of an antioxidant system has a significant role in an organism protection at an inflammation, this is connected with a neutralization of free radicals and reactive molecules producing of which increases in an oxidative stress condition. A dysfunction of antiradical enzymes can cause a progressing of a pathologic process and increase frequency of adverse outcomes in many diseases [20]. It is known that there is a multi-level antioxidant system and a complex of peroxidation regulatory processes in an organism [21]. At the same time in a hypoxia the concentration of oxygenates increases significantly and takes precedence of a norm by several times: components of peroxidative modification of biomolecules are collected, and their local increase is also regular and correlates with an intensity of a pathologic process causing changes in the cell morphology and internal organs tissues [22, 23].

At the cellular level in hepatocytes hypoxia there is a repression of response of tricarboxylic acids cycle because of a membrane transport defect as well as because of a decrease of a substrate amount and an activity of enzymatic systems in a energy lack condition, mitochondria dysfunction. These all leads to oxidation stress as there is discordance of prooxidant and antioxidant cell resources. That is why in cases where metabolic defects are the result of a severe intoxication and oxidation metabolism failure, it is possible to use antioxidative medications in a complex therapy [24, 25], including products with a modified isotopic composition [26, 27].

Taking the above into account the aim of the given research was to study the effect of the water

menu with a low D/H on morphological hepatocytes parameters in rabbits in modeling of an acute hypoxic liver damage.

MATERIAL AND METHODS

Animal experiments had been doing under section 11 of the World Medical Association's Declaration of Helsinki (1964), documents: Good laboratory practice in the Russian Federation (Order of the Ministry of Health of the Russian Federation, № 267 of 19.06.2003), International recommendations for experiments with animals (1985), requirements of the Order of the Ministry of Health of the Russian Federation, № 267 of 19.06.2003, "about approval of laboratory practice rules". The effect of the water with a low deuterium concentration on liver morphological parameters had been estimated in 40 male rabbits (weighing 2,5—3,1 kg) which were divided into the following groups:

group A — control group (n = 10);

group B — animals with a simulated acute liver hypoxic damage caused by a compression of a hepatoduodenal ligament during 20 minutes (n = 10);

group C — animals with a simulated acute liver hypoxic damage caused by a compression of a hepatoduodenal ligament during 20 minutes, and which preliminary had been getting linseed oil through an enteral feeding tube during 4 weeks (group of compare, n = 10);

group D — animals with a simulated acute liver hypoxic damage (n=10), caused by a compression of a hepatoduodenal ligament during 20 minutes, and which preliminary (during 6 weeks) had been getting water with a low deuterium level (40 ppm concentration) in relation to a natural deuterium level.

Morphological research of liver tissues of the experimental animals had been done by cytological and histological methods. For the cytological test there had been prepared impression smear of the studying organ after which it had been stained with azur-eosin according to a common procedure.

For the histological method the liver samples had been fixed in a 10% neutral formaline solution on 0.1 M phosphate buffer at pH 7.2—7.4. The liver

samples had been dehydrated then by putting them into a number of isopropanol solutions of a rising strength, and then the samples had been covered with wax. The given sample blocks had been sliced 3 μ m thick and stained with hematoxylin and eosin [28].

An isotopic determination (D/H) of blood and organ tissues of the detoxication system in the laboratory animals had been organized on the base of the "Diagnostics of Nanomaterials' Structure and Properties Common Use Center" Kuban State University (Krasnodar).

A determination of deuterium in a blood plasma was done by the NMR spectrometer JEOL JNM-ECA 400 MHz [29, 30]. Spectra filming had been done on the appropriate deuterium nucleus resonant frequency — 61.4 MHz. Filming parameters: 6.7 sec (acquisition time), 20 sec (relaxation delay), 5.6 ms (x-pulse), 0.15 Hz (resolution). Filming temperature — 25 °C, stability rate 0.2 °C. Measurements had been done using a 5 mm ampoule inside of which there was a strictly fixed sealed capillary with a mixture of deuterated and non-deuterated dimethylsulfoxide (DMSO) dimensioned by a defined concentration scale. The capillary emitted a ^2D NMR signal in a 3.4 ppm area (compared with $(\text{CD}_3)_4\text{Si}$), while a ^2D NMR HDO signal is in a 4.7 ppm (compared with $(\text{CD}_3)_4\text{Si}$).

The spectra processing included the evaluation of a proportion of integral intensities of a ^2D NMR HDO signal in the studying sample comparing to a ^2D NMR DMSO-D1 signal, the intensity of which was defined in the same conditions and standards — water samples with an accurate deuterium level (3.7 ppm, 51 ppm, 150 ppm). Each sample had been measured several times in order to reduce the experimental error. With this the determination accuracy of the deuterium concentration in biological samples was 2 ppm. Measurements calibration in biofluids had been done according to international standards SMOW (155.76 ppm), SLAP (89 ppm).

To evaluate an isotopic composition of lyophilized liver tissues of the laboratory animals there had been used an isotopic mass-spectrometer DELTA^{plus} (Finnigan, Germany) [31].

Statistical processing of data had been done by the method of variation statistics: the average mean of the given samples was calculated (M), mean-square deviation (σ), the difference between the groups was considered as accurate, and was determined with the help of nonparametric Mann-Whitney U-test ($p < 0.05$).

RESULTS AND DISCUSSION

The studying of an isotopic composition of plasma revealed a decrease of the deuterium concentration by 32% in the rabbits from the group D comparing with the control group A ($152,1 \pm 2,8$ ppm, $p < 0.05$). At this, in groups B and C there had not been found significant difference comparing with group A. The deuterium concentration in liver tissues of the rabbits from the group D was 123.8 ± 1.3 ppm which is 9% less ($p < 0,05$) than the analogical parameter in the group of control A at the same time there were no significant difference in the deuterium concentration in liver tissues of the rabbits from groups B and D comparing with the group A.

The results of the morphological study of liver microslides of the rabbits allow to verify hepatoprotective effect of the used nutrition methods of correcting.

In the studying the morphological changes in the rabbits from the A group there was noted that hepatocytes have a typical to this kind of cells shape close to polygonal, a structure of hepatic tubules is

well pronounced; cells' nucleus are round, chromatin is of a various decondensation degree, many of the nucleus have nucleoles which show a good synthetic activity, the signs of karyopyknosis and karyorhexis are not noted. The cytoplasm is slightly basophilic, its stain is uniform, no features of degeneration; bloodfilling is from slight to moderate (Fig. 1).

During the studying of the morphological change in the rabbits of the group B there had been noted that there were inhomogeneity of the microscopic slice of the liver. Through all of the microslide interstitial tissue edema and decompensation of hepatic tubules; liver cells are visibly enlarged, hyperchromia of a cytoplasm is noted with a slight and moderate cloudy and adipose degeneration; chromatin in cells nucleus is condensed, there are evident signs of karyopyknosis and karyorhexis. There are the areas of a sclerosis in interlobular hepatic ductules and venous system stasis and congestion with an adipose degeneration of hepatocytes; stasis and congestion is often accompanied by a perivascular infiltration (Fig. 2).

During the studying of the morphological change in the rabbits of the group C there had been noted that a liver microstructure is inhomogeneous; hepatocytes are with evident features of degeneration — hyperchromia of a cytoplasm with vacuolation and a slight adipose degeneration; decompensation of hepatic tubules is moderate; nucleus chromatin is

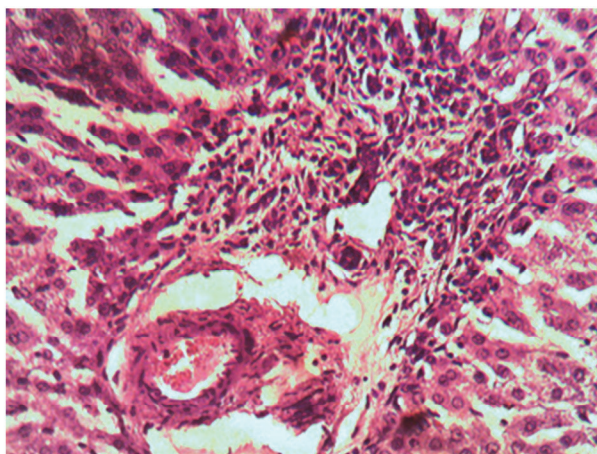


Fig. 1. Liver of the rabbit from the A group (hematoxylin-eosin staining; lense apo- 20× ocular K10×)

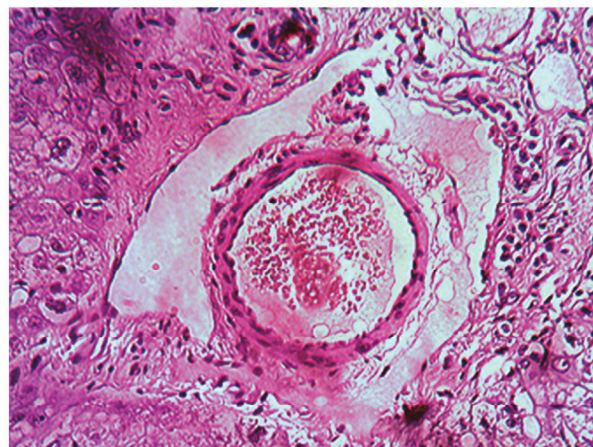


Fig. 2. Liver of the rabbit from the B group (hematoxylin-eosin staining; lense apo- 20× ocular K10×)

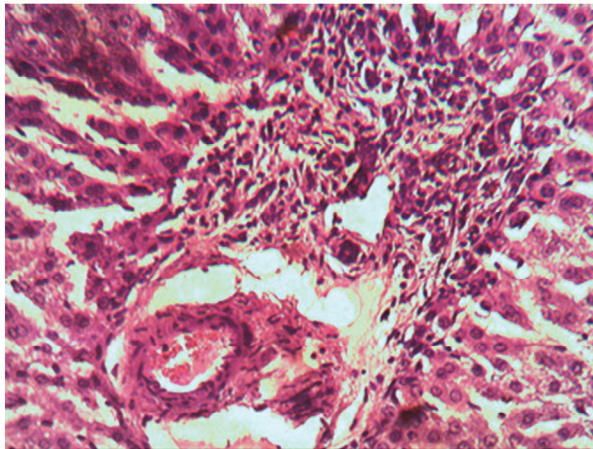


Fig. 3. Liver of the rabbit from the C group (hematoxylin-eosin staining; lense apo- 20× ocular K10×)

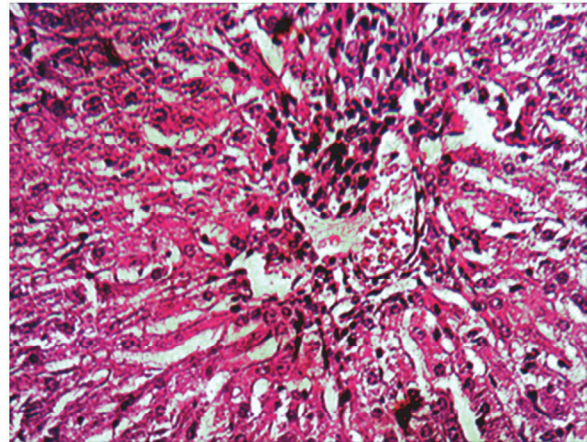


Fig. 4. Liver of the rabbit from the D group (hematoxylin-eosin staining; lense apo- 20× ocular K10×)

condensated, many of the nucleuses are with evident signs of karyopyknosis. Hepatocytes are visibly enlarged comparing with the control; there are areas of liver parenchyma with an evident congestion in a venous system, signs of liver tissue edema and moderate adipose degeneration. At the same time some of the liver parenchyma areas have hystoarchitectonics and cytoarchitectonics which does not significantly differ from the animals of the control group. It should be noted that even in such a “safe” parenchyma areas there are still stasis of erythrocytes, interstitial parenchyma edema and slight dystrophic signs in hepatocytes cytoplasm (Fig. 3).

During the studying of the morphological change in the rabbits of the group D there had been noted that hepatocytes are of a typical polygonal shape, a structure of hepatic tubules is well pronounced; though, liver microstructure is inhomogeneous in various areas of the microslices; liver cells are diminished in size, a hyperchromia of a cytoplasm is evident with signs of a slight cloudy and adipose degeneration. The signs of karyopyknosis and karyorhexis had not been noted. The cytoplasm is slightly basophilic, its stain is not always uniform; vessels are bloodfilled, there are blood stasis signs noted (Fig. 4). As we can see, on the base of a visual morphological study of the liver microslices of the rabbits under the acute experiment (compression of a hepatoduodenal ligament), we may confirm that the water menu with a low deuterium concentration (40 ppm)

have more hepatoprotective effect comparing with nutritional correction by the use of alimentary phyto-genic factors (linseed oil). At the same time both of the correcting factors accurately surpassed analogical parameters in the rabbits with an ischemic liver damage which received regular drinking water (150 ppm) without cytoprotective features (according to the study results).

CONCLUSION

In the adding of the DDW into the water menu of the rabbits there had been revealed an accurate decrease of deuterium concentration as in a blood plasma (by 32%) as in liver tissues (9%), which shows the possible correction of isotopic composition of internal environment and organs by the use of the products with a low deuterium concentration. Taking to account the received results we can speak about the experimental proof of the practicability of a complex use of alimentary phyto-genic antioxidant factors, and, probably a combined use of these factors and a water menu with a low deuterium concentration (40 ppm) in patients with an ischemic liver damage, including patients on the rehabilitation post-surgical period.

Acknowledgment. This work was supported by the State Task of the Ministry of Health of the Russian Federation by state assignment (28.01.2015, part 1, chapter 1), the grant of the President of the Russian Federation (МК-3359.2017.4).

REFERENCES

- Belyakin S.A., Botrov A.N., Plyusnin S.V. The role of liver biopsy in the diagnosis of alcoholic hepatitis. *Military medical journal*. 2011. V. 5. P. 68—69.
- Isayama F., Hines I.N., Kremer M., Milton R.J., Byrd C.L., Perry A.W., McKim S.E., Parsons C., Rippe R.A., Wheeler M.D. LPS signaling enhances hepatic fibrogenesis caused by experimental cholestasis in mice. *Am. J. Physiol. Gastrointest. Liver Physiol*. 2006. V. 290. P. 1318—1328.
- Chang C.Y., Argo C.K., Al-Osaimi A.M., Caldwell S.H. Therapy of NAFLD: insulin sensitizing agents. *J. Clin. Gastroenterol*. 2006. V. 40 (1). P. 51—60.
- Udut V.V., Dygai A.M., Vengerovsky A.I. Effects of phospholipid hepatoprotectors on apoptosis during experimental liver pathology induced by isoniazid and paracetamol. *Bulletin of experimental biology and medicine*. 2013. V. 154 (5). P. 614—617.
- Rehakova R., Klimentova J., Cebova M., Barta A., Matuskova Z., Labas P. Effect of deuterium-depleted water on selected cardiometabolic parameters in fructose-treated rats. *Physiol. Res*. 2016. V. 65 (3). P. 401—407.
- Parmon V.N. On the possibility of observing kinetic isotopic effects in the life cycles of living organisms at ultralow concentrations of deuterium. *Her. Russ. Acad. Sci*. 2015. V. 85. P. 170—172.
- Dzhimak S.S., Basov A.A., Fedulova L.V., Didikin A.S., Bikov I.M., Arcybasheva O.M., Naumov G.N., Baryshev M.G. Correction of metabolic processes in rats during chronic endotoxemia using isotope (D/H) exchange reactions. *Biology Bulletin*. 2015. V. 42 (5). P. 440—448.
- Strekalova T., Evans M., Chernopiatko A., Couch Y., Costa-Nunes J., Cespuglio R. Deuterium content of water increases depression susceptibility: the potential role of a serotonin-related mechanism. *Behavioural Brain Research*. 2015. V. 277. P. 237—244.
- Dzhimak S.S., Basov A.A., Volchenko N.N., Samkov A.A., Fedulova L.V., Baryshev M.G. Changes in the functional activity of mitochondria isolated from the liver of rat that passed the preadaptation to ultra-low deuterium concentration. *Doklady Biochemistry and Biophysics*. 2017. V. 476. P. 323—325.
- Areshidze D.A., Timchenko L.D., Kozlova M.A., Syomin I.A., Rzhepakovsky I.V., Piskov S.I. Influence of biologically active substance “STEMB” on a morphofunctional condition of a liver and kidneys of rats at an experimental hepatorenal syndrome. *Journal of Pharmacy and Nutrition Sciences*. 2015. V. 5 (3). P. 186—193.
- Grigorenko D.Y. Peculiarities of the cellular composition of splenic lymphoid tissue in mice after long-term use of light water and irradiation. *Morfologiya*. 2015. V. 148 (4). P. 19—23.
- Basov A.A., Bykov I.M. Comparative characteristic of antioxidant capacity and energy content of some foods. *Voprosy Pitaniia*. 2013. V. 82 (3). P. 77—80.
- Fatemi F., Dadkhah A., Akbarzadeh K., Dini S., Hatami S., Rasooli A. Hepatoprotective effects of deuterium depleted water (DDW) adjuvant with Satureja rechingeri essential oils. *Electronic Journal of Biology*. 2015. V. 11 (2). P. 23—32.
- Gins M.S., Gins V.K., Baikov A.A., Rabinovich A.M., Kononkov P.F., Solntsev M.K. Antioxidant content in medicinal plants and vegetables with therapeutic potential for treating cancer. *Questions of biological, medical and pharmaceutical chemistry*. 2013. V. 2. P. 10—15.
- Bykov I.M., Basov A.A., Bykov M.I., Khanfer'ian R.A. Comparative evaluation of antioxidant activity and content of prooxidant factors in different classes of foods. *Voprosy Pitaniia*. 2014. V. 83 (4). P. 75—81.
- Kravchenko L.V., Gladkikh O.L., Avrenyeva L.I., Tutelyan V.A. In vitro and in vivo studies of antioxidant properties of indole-3-carbinol. *Questions of biological, medical and pharmaceutical chemistry*. 2008. V. 4. P. 18—23.
- Basov A.A., Bykov I.M. Change of blood antioxidant capacity of experimental animals during nutritional correction under oxidative stress. *Voprosy Pitaniia*. 2014. V. 82 (6). P. 75—81.
- Cruz A., Padillo F.J., Tunez I. Melatonin protects against renal oxidative stress after obstructive jaundice in rats. *Eur. J. Pharmacol*. 2001. V. 425 (2). P. 135—139.
- Bykova N.I., Basov A.A., Melkonyan K.I., Alekseenko E.A., Popov K.A., Bykov I.M. Non-invasive monitoring for local immune and antioxidant resistance in patients with ischemic heart disease and type 2 diabetes. *Medical news of North Caucasus*. 2016. V. 11 (2). P. 147—149.
- Basov A.A., Baryshev M.G., Bykov I.M., Pavluchenko I.I., Dzhimak S.S., Sepiashvili R.I. Effect of water with a modified isotopic composition on the performance on the intensity of free-radical processes in experiment of laboratory animals. *Allergology and Immunology*. 2012. V. 13 (4). P. 314—320.
- Basov A.A., Akopova V.A., Bykov I.M. Changing the parameters of prooxidant-antioxidant system in blood and oral fluid of patients with ischemic heart disease and type 2 diabetes mellitus. *International Journal on Immunorehabilitation*. 2013. V. 15 (2). P. 84—86.
- Rasooli A., Fatemi F., Akbarzadeh K., Dini S., Bahremand S. Synergistic protective activity of deuterium depleted water (DDW) and satureja rechingeri essential oil on hepatic oxidative injuries induced by acetaminophen in rats. *Journal of Essential Oil Bearing Plants*. 2016. V. 19 (5). P. 1086—1101.
- Bykov M.I., Basov A.A. Change of parameters in prooxidant-antioxidant bile system in patients with the obstruction of bile-excreting ducts. *Medical news of North Caucasus*. 2015. V. 10 (2). P. 131—135.
- Okada K., Shoda J., Kano M., Suzuki S., Ohtake N., Yamamoto M. Inchinkoto, a herbal medicine, and its ingredients dually exert Mrp2/MRP2-mediated choleresis and Nrf2-mediated antioxidative action in rat livers. *Am.*

- J. Physiol. Gastrointest. Liver Physiol.* 2007. V. 292. P. 1450—1463.
25. Belyaev A.N., Mokshina E.I., Belyaev S.A., Melnikova D.V., Kostin S.V., Khvostunov S.I. Effectiveness of intraportal mexidol infusions in the treatment of obstructive jaundice. *Surgery journal of them. N.I. Pirogova.* 2009. V. 9. P. 66—69.
26. Dzhimak S.S., Barishev M.G., Basov A.A., Timakov A.A. Influence of deuterium depleted water on freeze dried tissue isotopic composition and morphofunctional body performance in rats of different generations. *Biophysys.* 2014. V. 59 (4). P. 614—619.
27. Bykovi M.I., Dzhimak S.S., Basovi A.A., Arcybasheva O.M., Shashkov D.I., Baryshev M.G. Comparative characteristics of the isotopic D/H composition and antioxidant activity of freshly squeezed juices from fruits and vegetables grown in different geographical regions. *Voprosy Pitaniia.* 2015. V. 84 (4). P. 89—96.
28. Korzhevsky D.E., Gilyarov A.V. Fundamentals of histological technique. Moscow: GEOTAR Media. 2005. 608 p.
29. Dzhimak S.S., Basov A.A., Kopytov G.F., Kashaev D.V., Sokolov M.E., Artsybasheva O.M., Sharapov K.S., Baryshev M.G. Application of NMR spectroscopy to the determination of low concentrations of nonradioactive isotopes in liquid media // *Russian Physics Journal.* 2015. V. 58 (7). P. 923—929.
30. Samkov A.A., Dzhimak S.S., Barishev M.G., Volchenko N.N., Khudokormov A.A., Samkova S.M. The effect of water isotopic composition on Rhodococcus erythropolis biomass production. *Biophysys.* 2015. V. 60 (1). P. 107—112.
31. Baryshev M.G., Basov A.A., Bolotin S.N., Dzhimak S.S., Kashaev D.V., Fedosov S.R., Frolov V.Y., Shashkov D.I., Lysak D.A., Timakov A.A. NMR, EPR, and mass spectroscopy estimates of the antiradical activity of water with modified isotope composition. *Bulletin of the Russian Academy of Sciences. Physics.* 2012. V. 76 (12). P. 1349—1352.

DOI: 10.22363/2313-0245-2018-22-1-120-126

ИЗМЕНЕНИЕ МОРФОЛОГИЧЕСКИХ ПОКАЗАТЕЛЕЙ ПЕЧЕНИ У КРОЛИКОВ ПРИ МОДЕЛИРОВАНИИ ГИПОКСИИ, КОРРИГИРУЕМОЙ ПОТРЕБЛЕНИЕМ ПИТЬЕВОГО РАЦИОНА С МОДИФИЦИРОВАННЫМ ИЗОТОПНЫМ D/H СОСТАВОМ

М.И. Быков^{1,2}, М. Чихладзе³, В.В. Щава², А.А. Елкина⁴, И.М. Быков¹,
К.А. Попов¹, А.В. Моисеев⁴, М.Г. Барышев⁴

¹Федеральное государственное бюджетное образовательное учреждение высшего образования «Кубанский государственный медицинский университет» Министерства здравоохранения Российской Федерации, Краснодар, Россия;

²ГБУЗ «Научно-исследовательский институт — Краевая клиническая больница № 1 имени профессора С.В. Очаповского» Министерства здравоохранения Краснодарского края, Краснодар, Россия;

³Национальный Институт Аллергологии, астмы и клинической иммунологии Национальной Академии Наук Грузии, Цхалтубо, Грузия;

⁴Федеральное государственное бюджетное образовательное учреждение высшего образования «Кубанский государственный университет», Краснодар, Россия;

В работе представлены данные, свидетельствующие о способности питьевого рациона с пониженным содержанием дейтерия уменьшать повреждение тканей печени при моделировании гипоксии путем пережатия гепатодуоденальной связки. Показано, что потребление deuterium depleted water (DDW) достоверно уменьшает концентрации дейтерия в плазме крови (на 32%) и в тканях печени (на 9%), что свидетельствует об эффективности коррекции изотопного состава внутренних сред и органов с помощью продуктов с пониженным содержанием дейтерия. Также установлено, что использование DDW с гепатопротекторными целями по своей эффективности не уступает некоторым антиоксидантам липофильного происхождения. Все это позволяет проводить сочетанное использование растительных антиоксидантных факторов и питьевого рациона с пониженным содержанием дейтерия (40 ppm) для коррекции морфологических повреждений печени при ее ишемическом поражении.

Ключевые слова: дейтерий, печень, кролики, морфология, гипоксия

Ответственный за переписку:

Быков Илья Михайлович, д.м.н., профессор, заведующий кафедрой фундаментальной и клинической биохимии, Кубанский государственный медицинский университет, Краснодар. E-mail: bikov_mi@mail.ru

Поступила 12.02.2018

Принята 16.03.2018